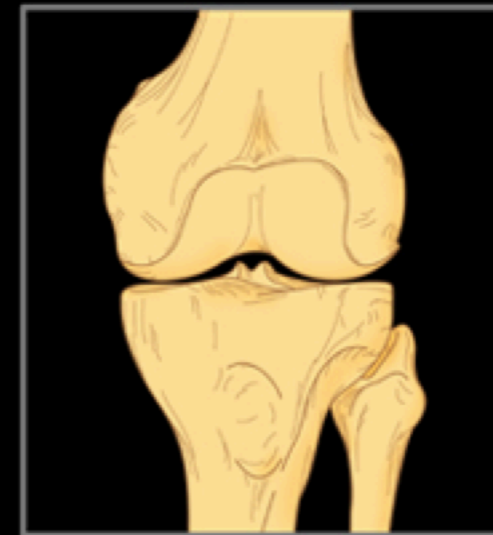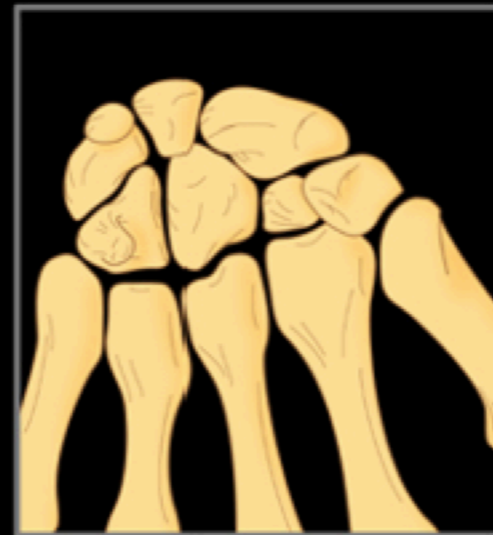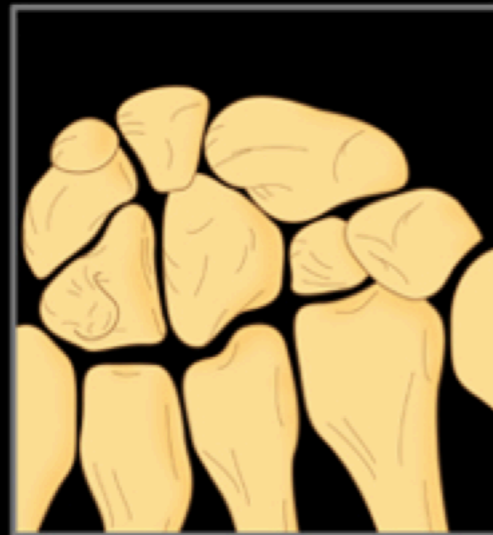


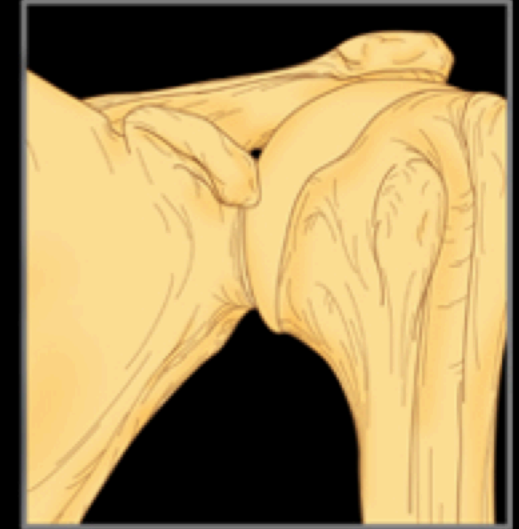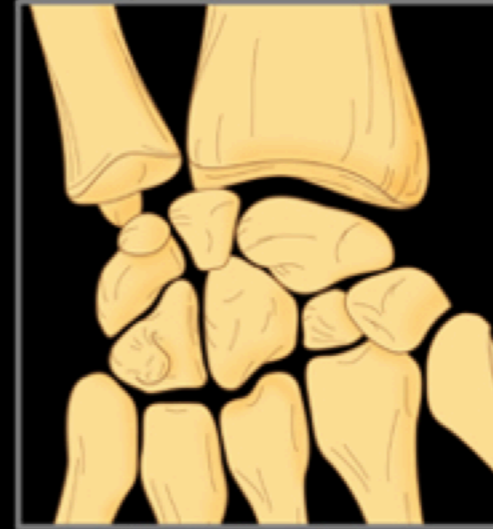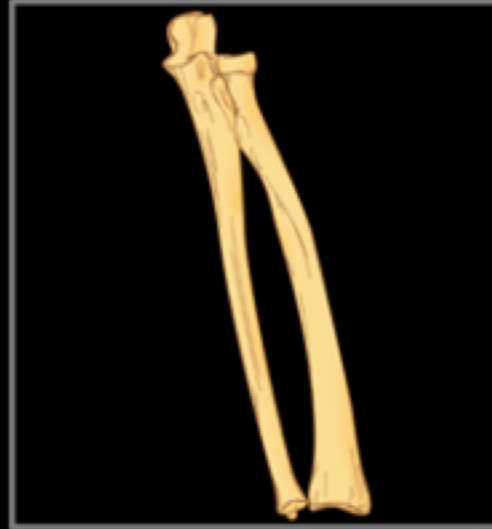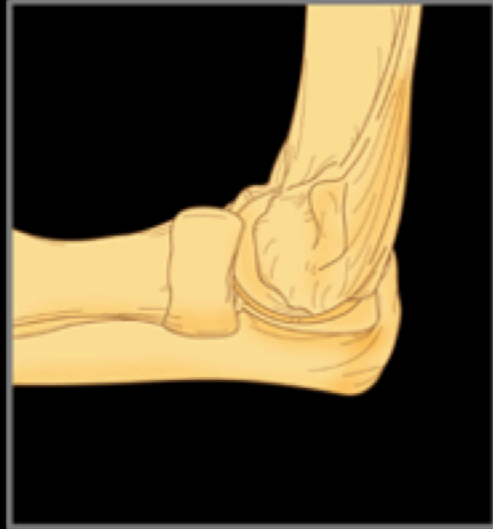Arthrology

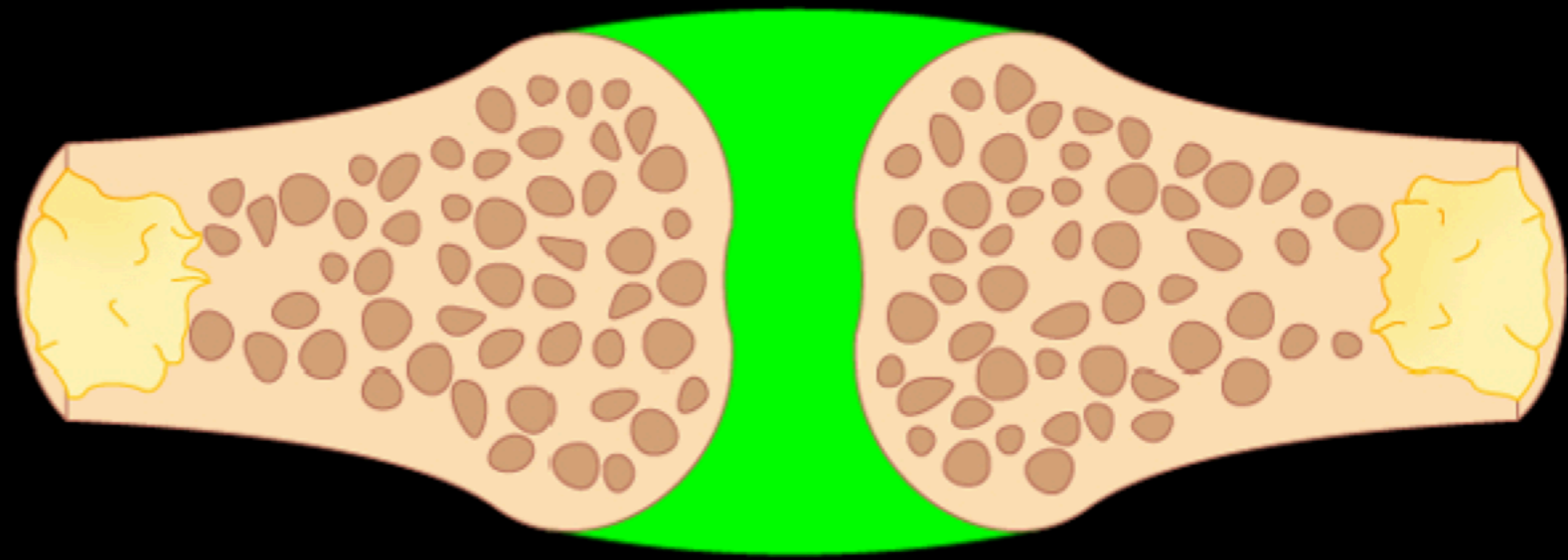


Arthrology

Classification of Joints

Synarthroses - Two Subcategories

Fibrous joints

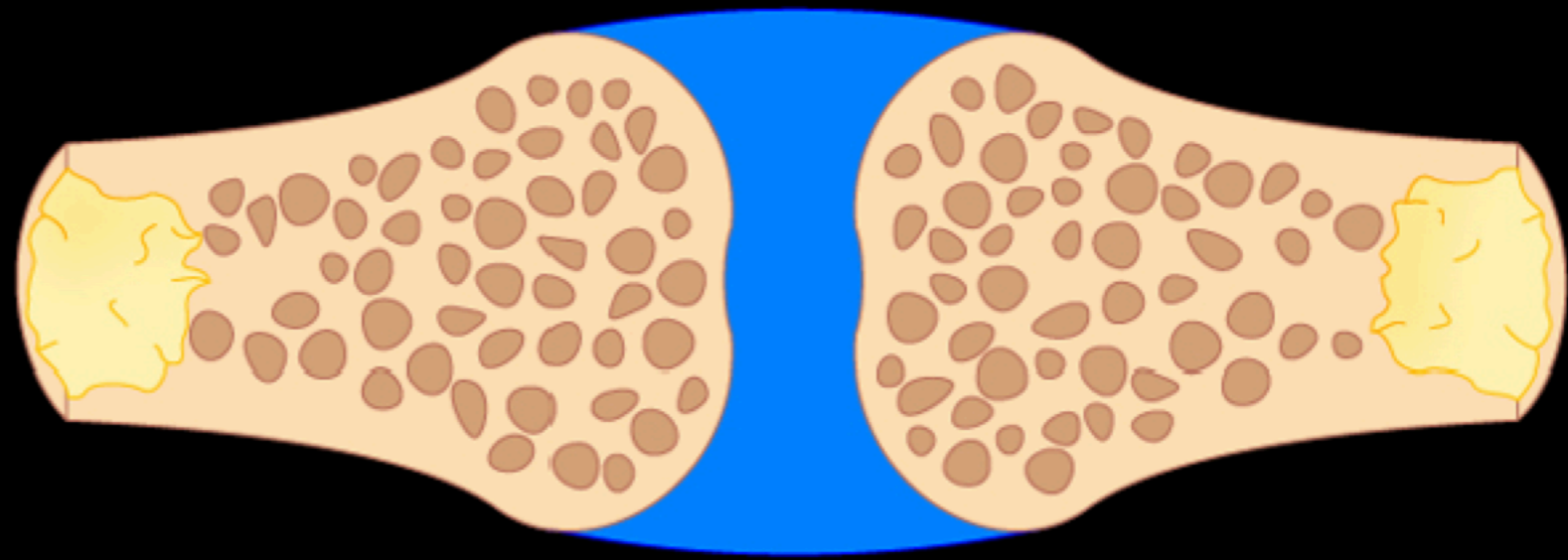


Arthrology

Classification of Joints

Synarthroses - Two Subcategories

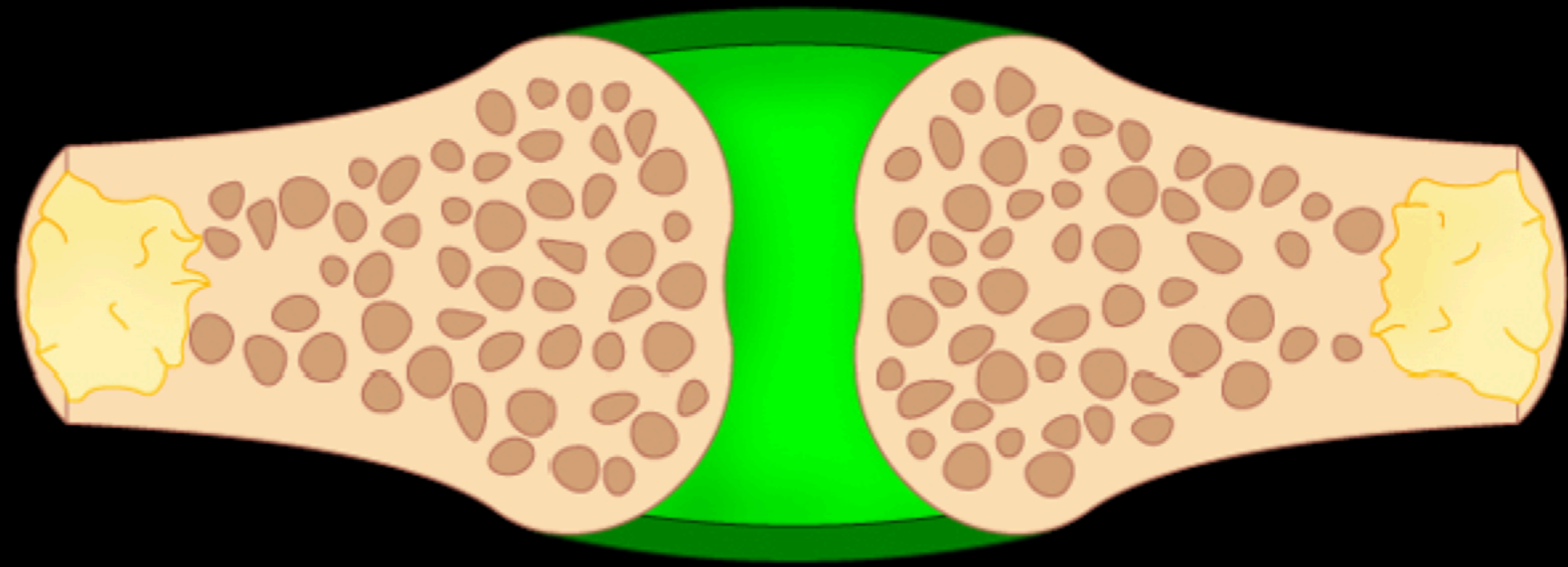
Cartilaginous joints



Arthrology

Classification of Joints

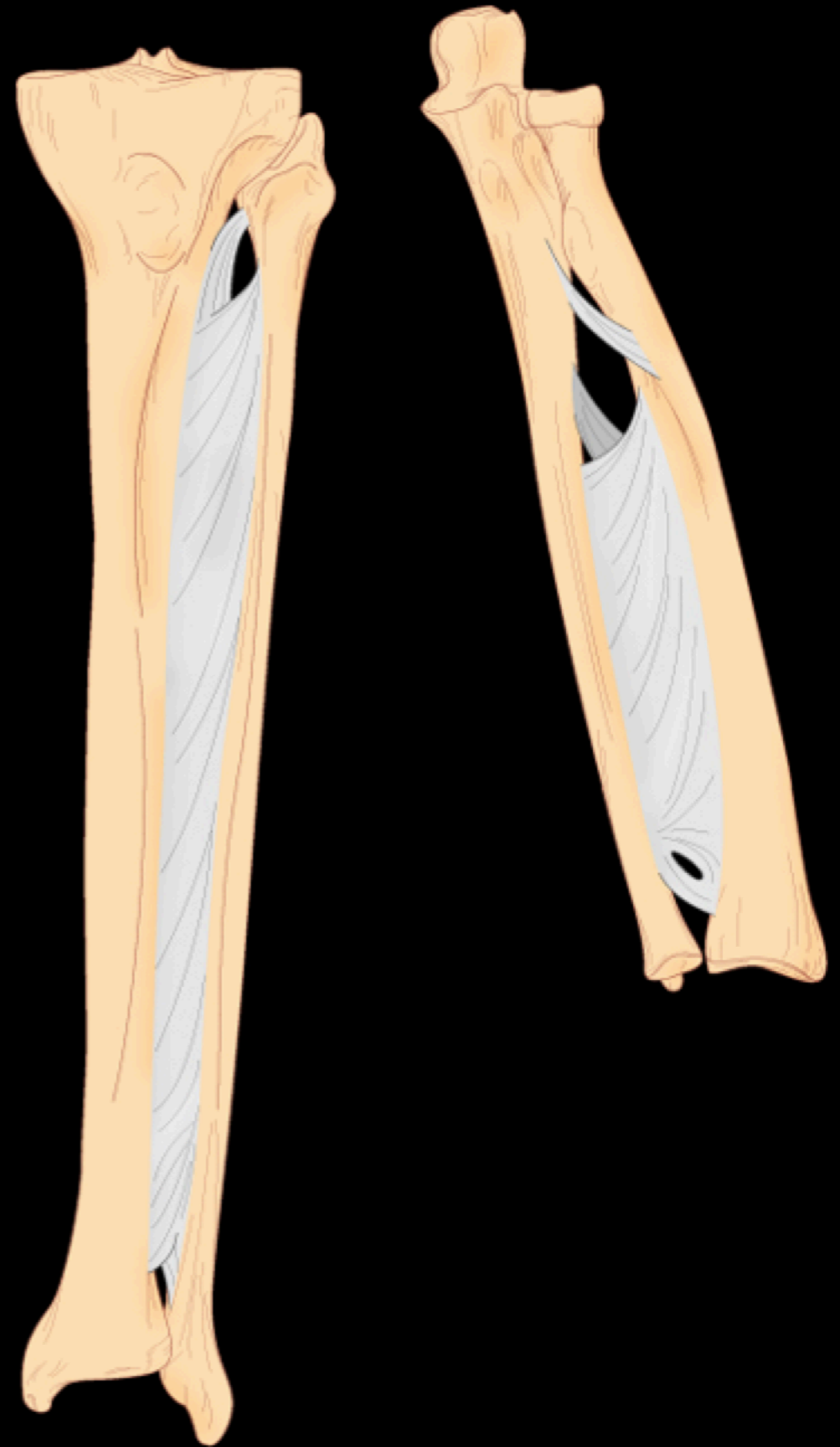
Diarthrosis or Synovial Joint



Arthrology

Fibrous Joints

Interosseous Membrane

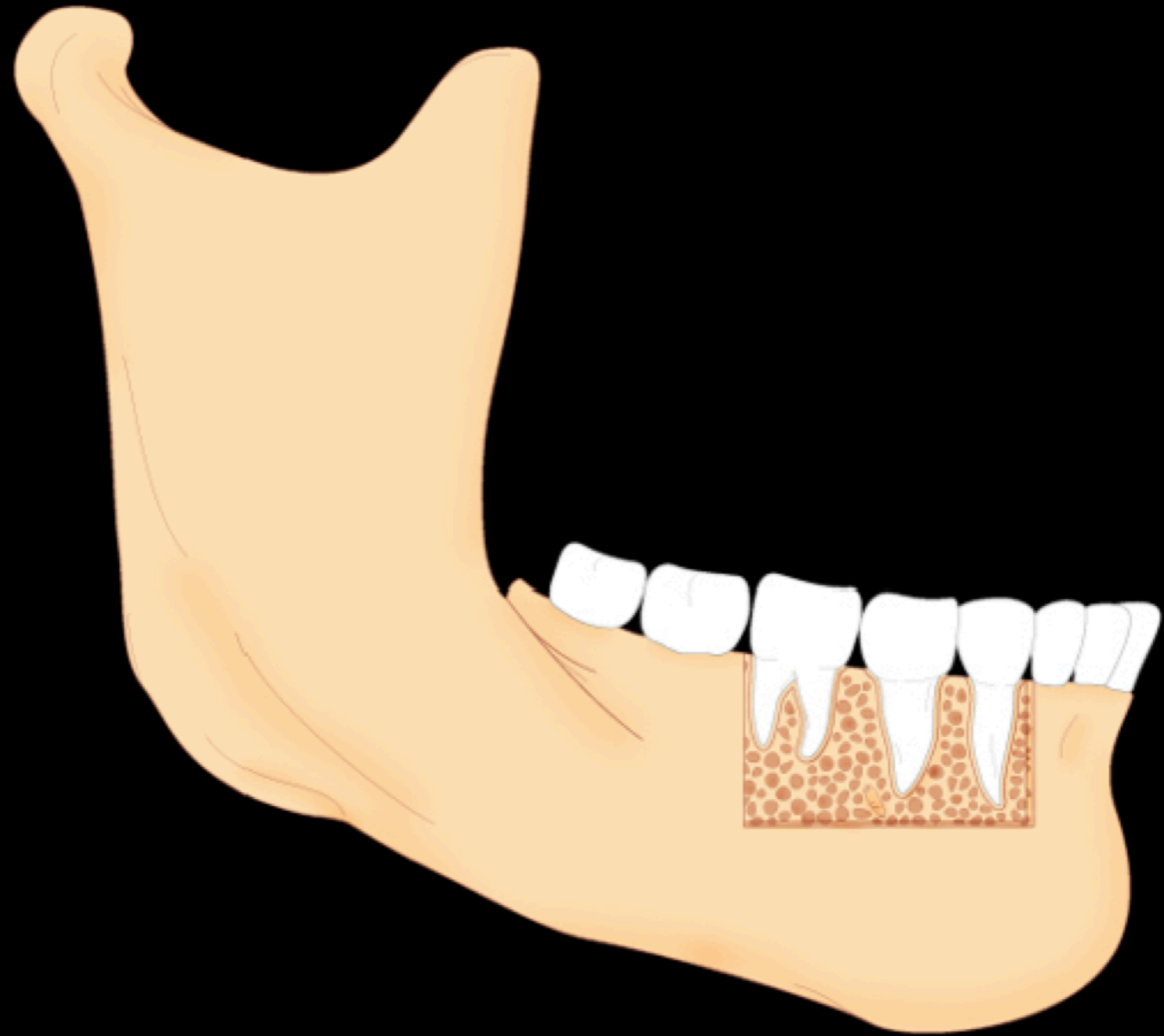


Arthrology

Fibrous Joints

Syndesmosis

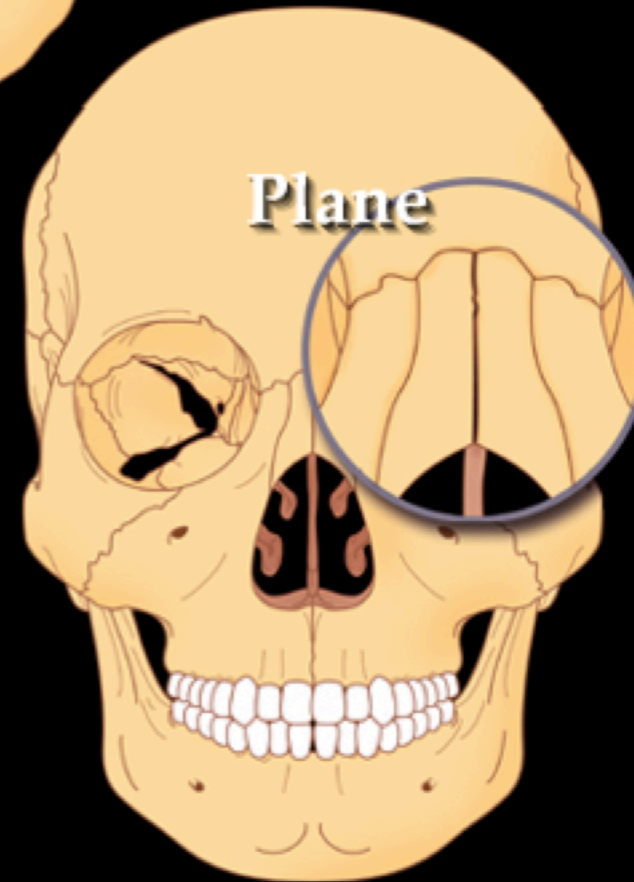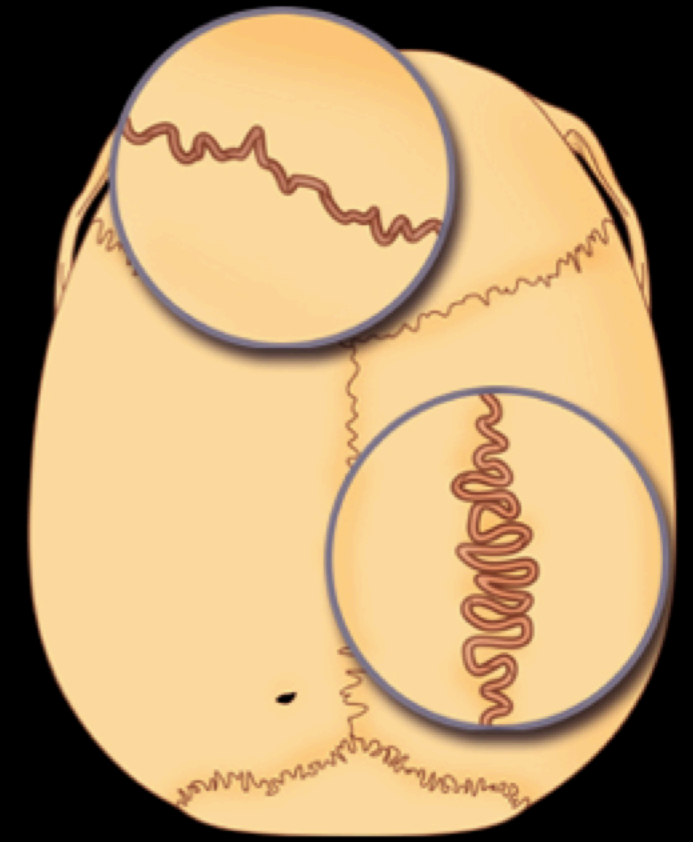
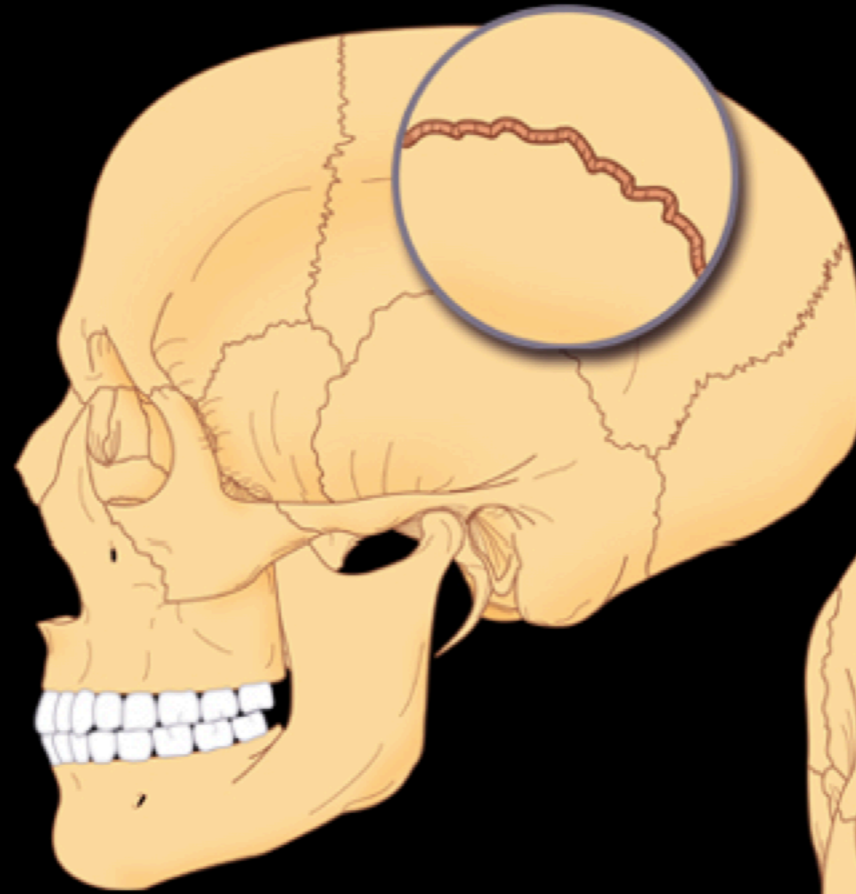
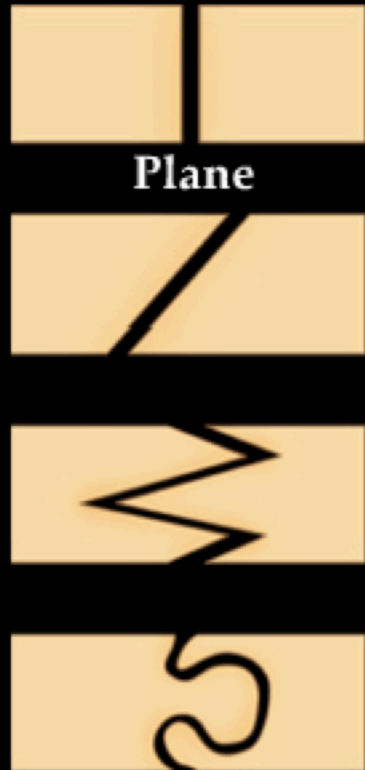Gomphosis



Anthropology

Fibrous Joints

Sutures



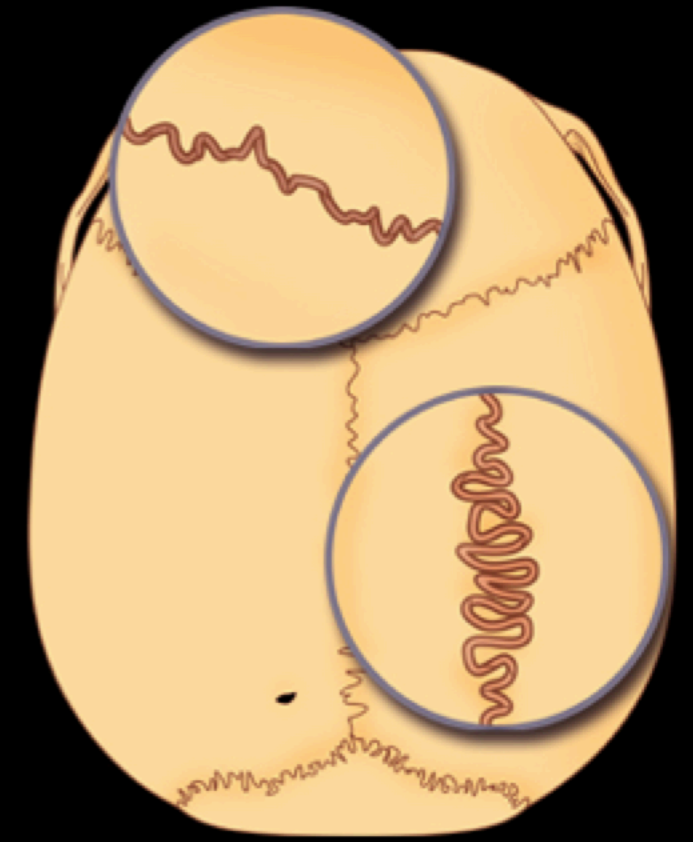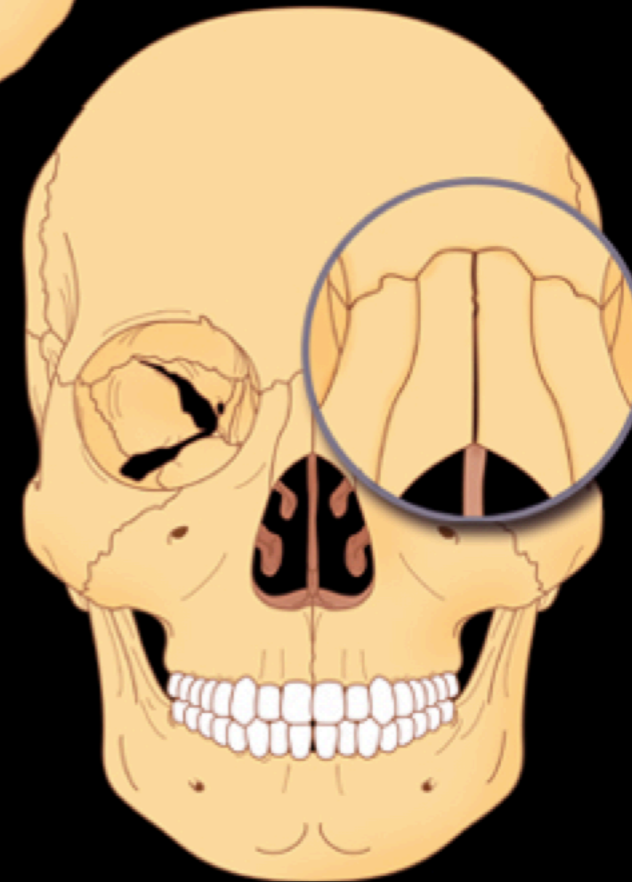
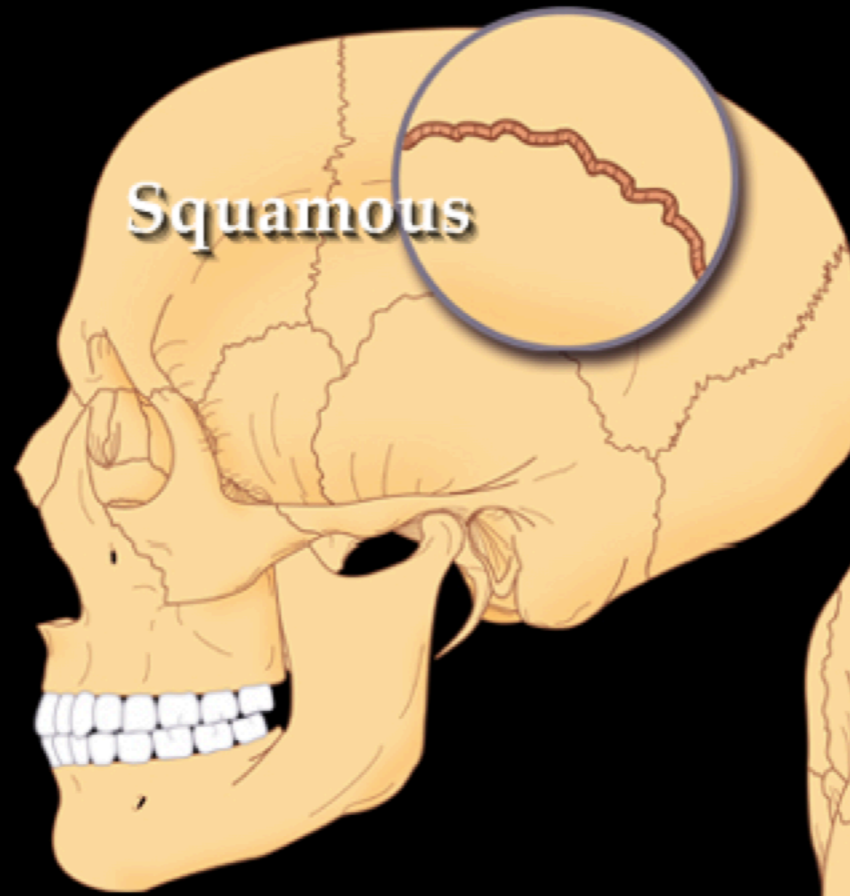
Anthropology

Fibrous Joints

Sutures



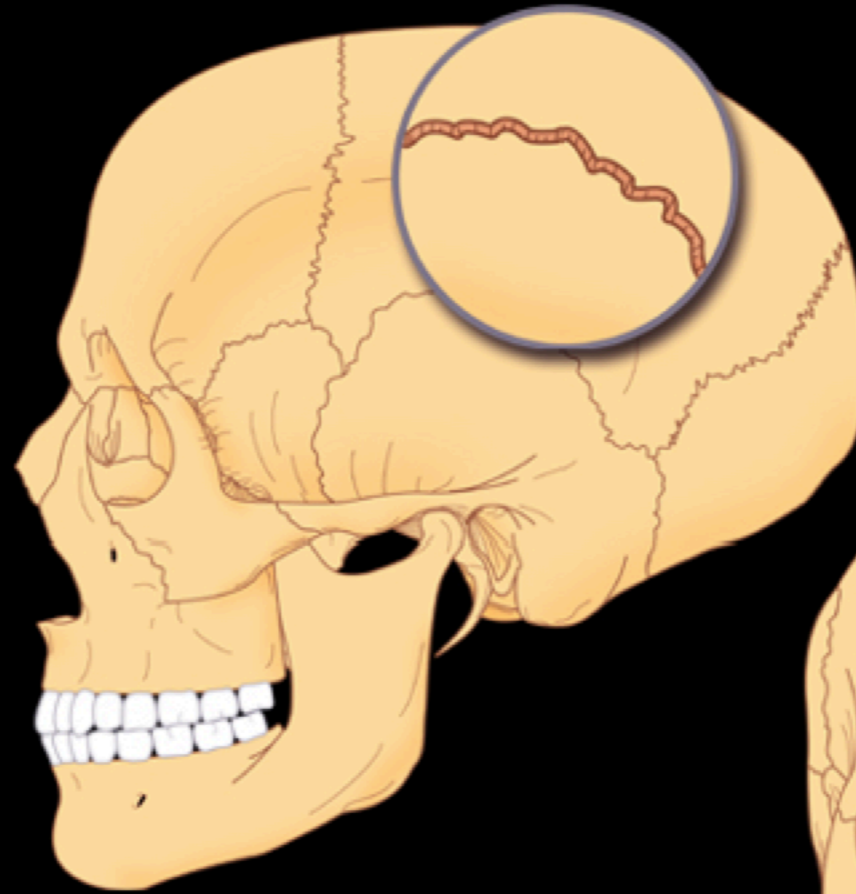
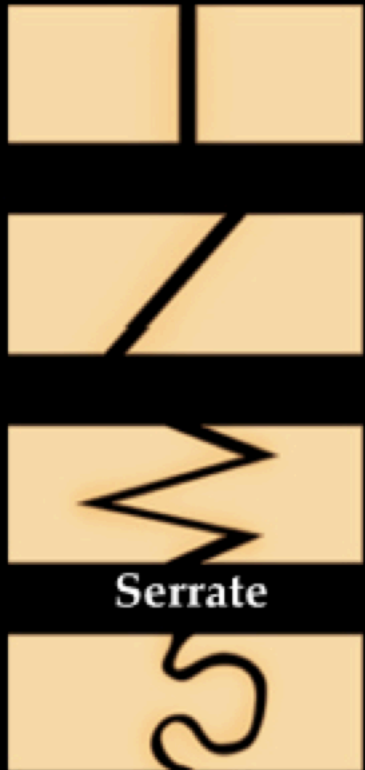Squamous



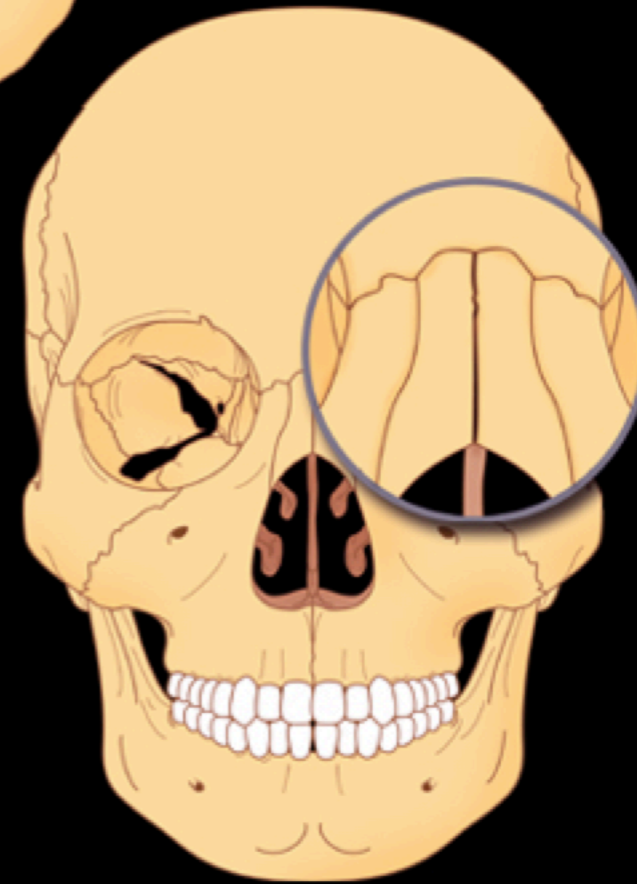
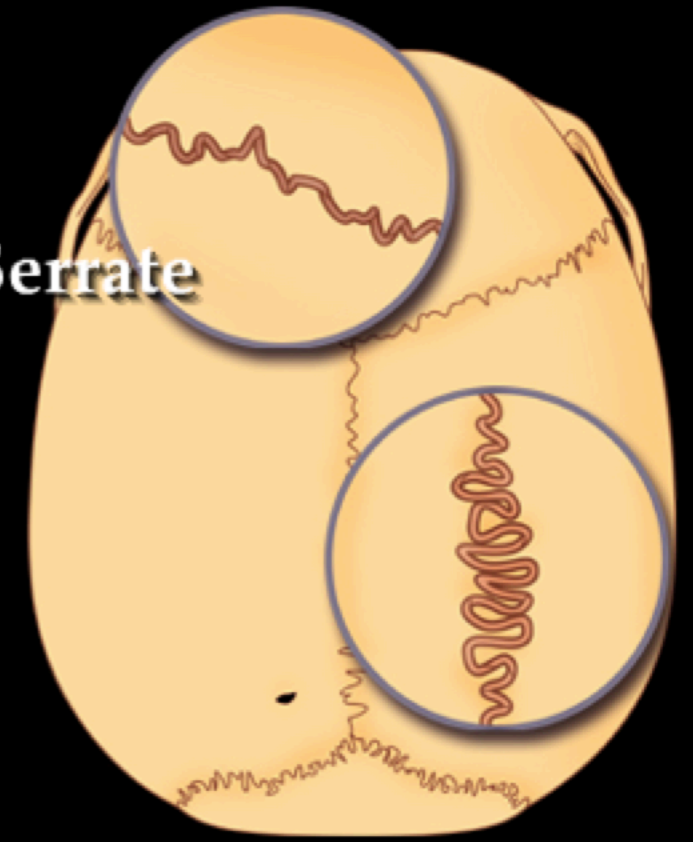
Anthropology

Fibrous Joints

Sutures

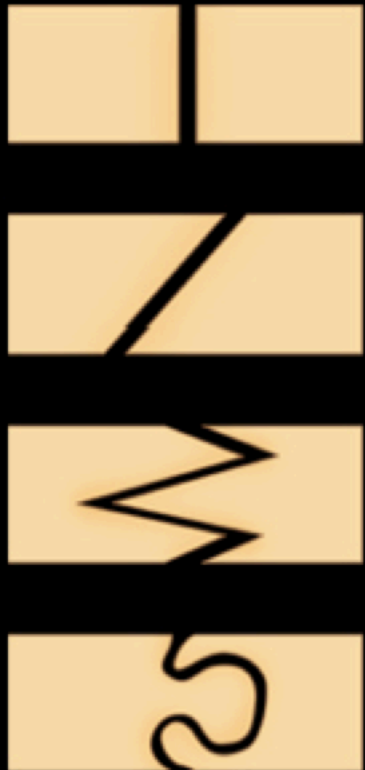

Serrate

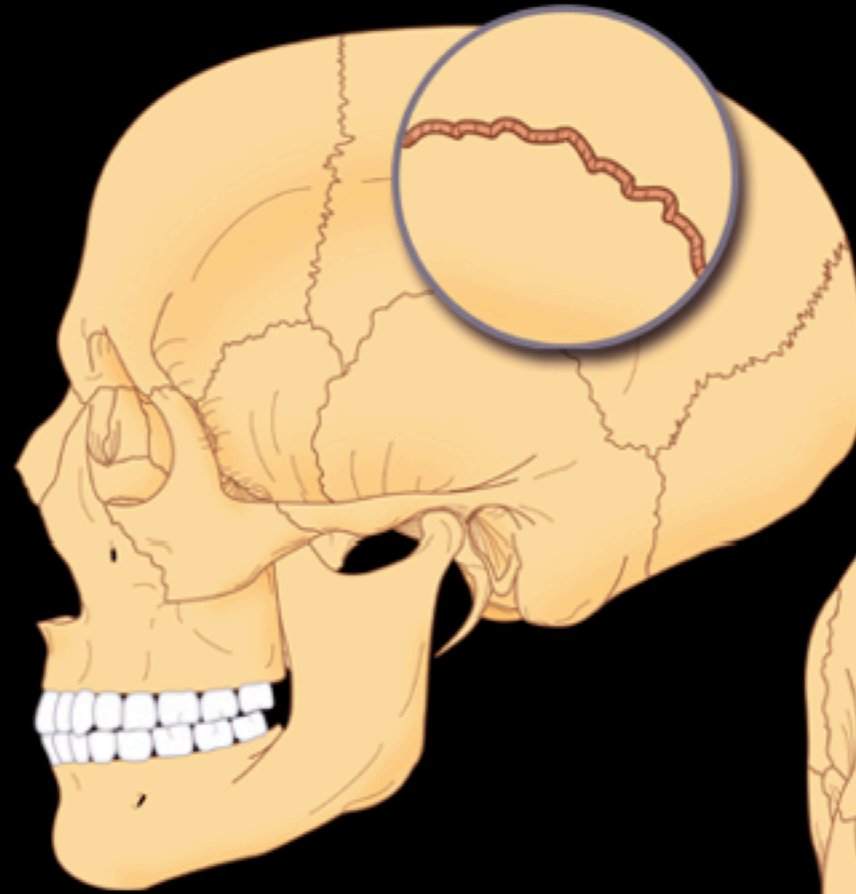


Anthropology

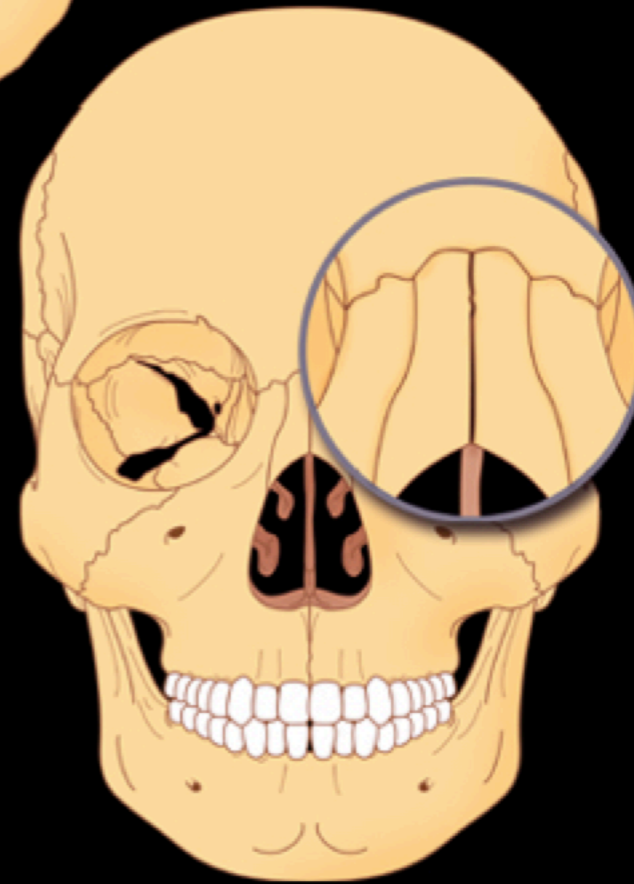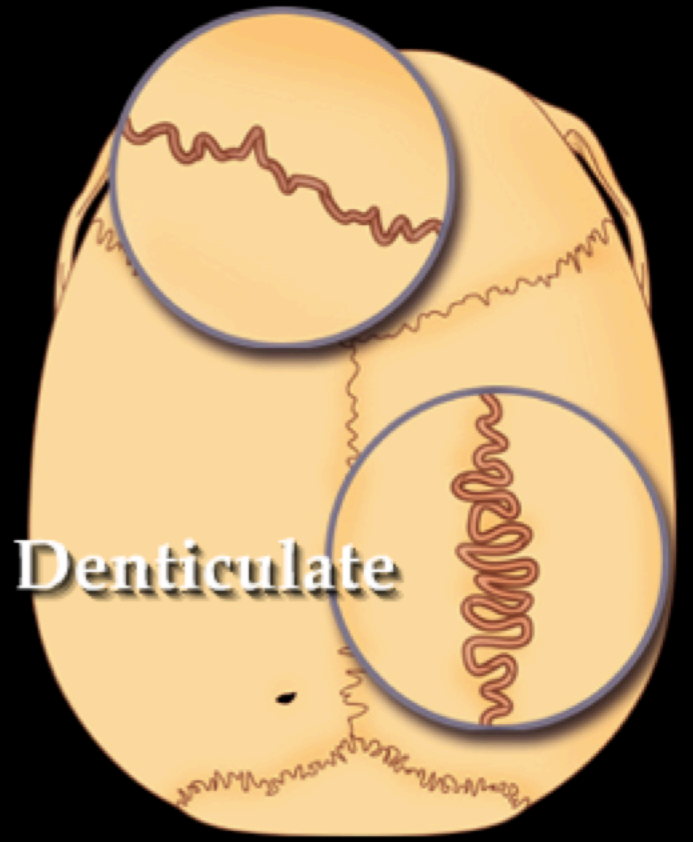
Sutures



Denticulate



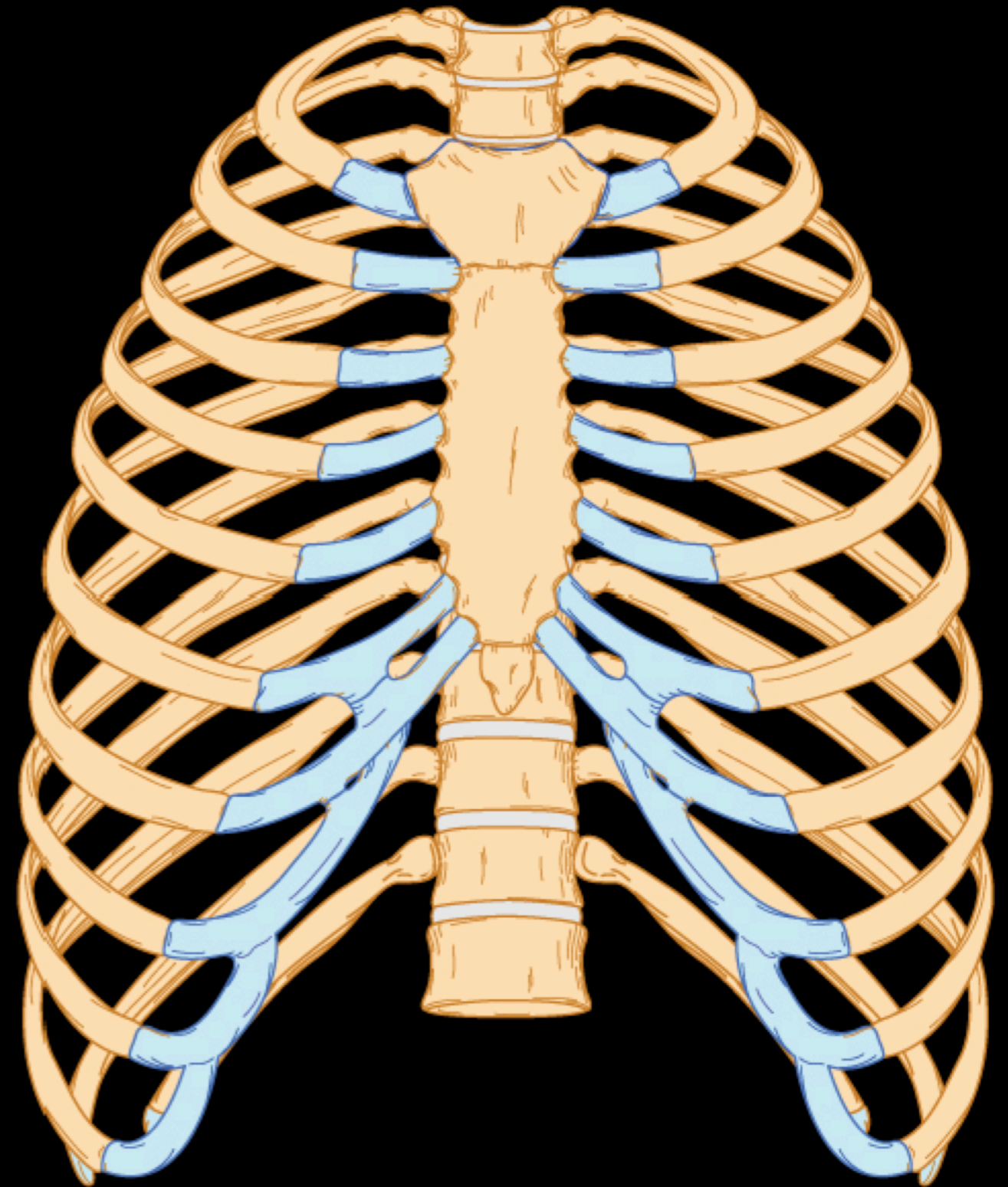
Denticulate



Arthrology

Cartilaginous Joints

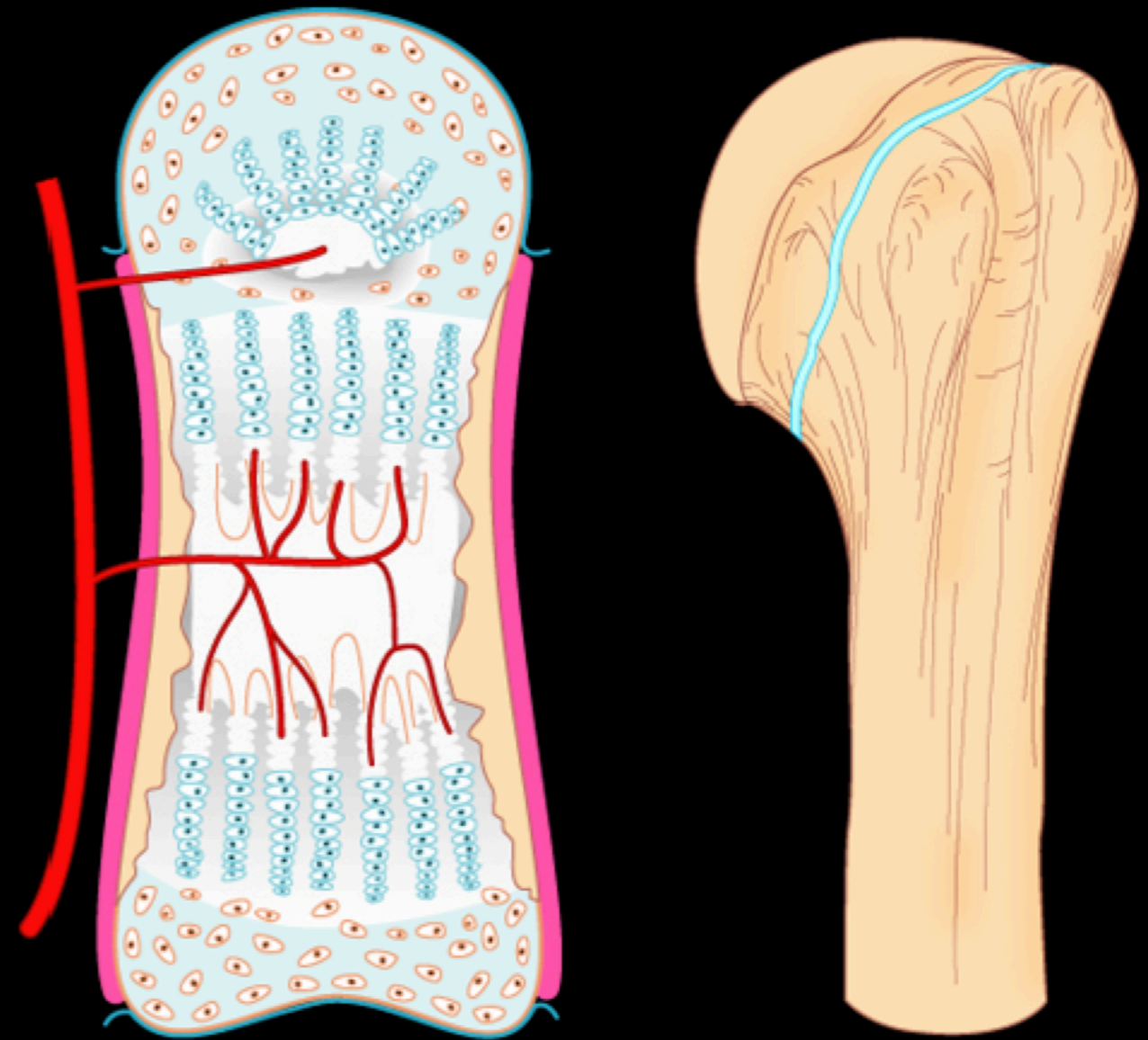
Synchondrosis



Arthrology

Cartilaginous Joints

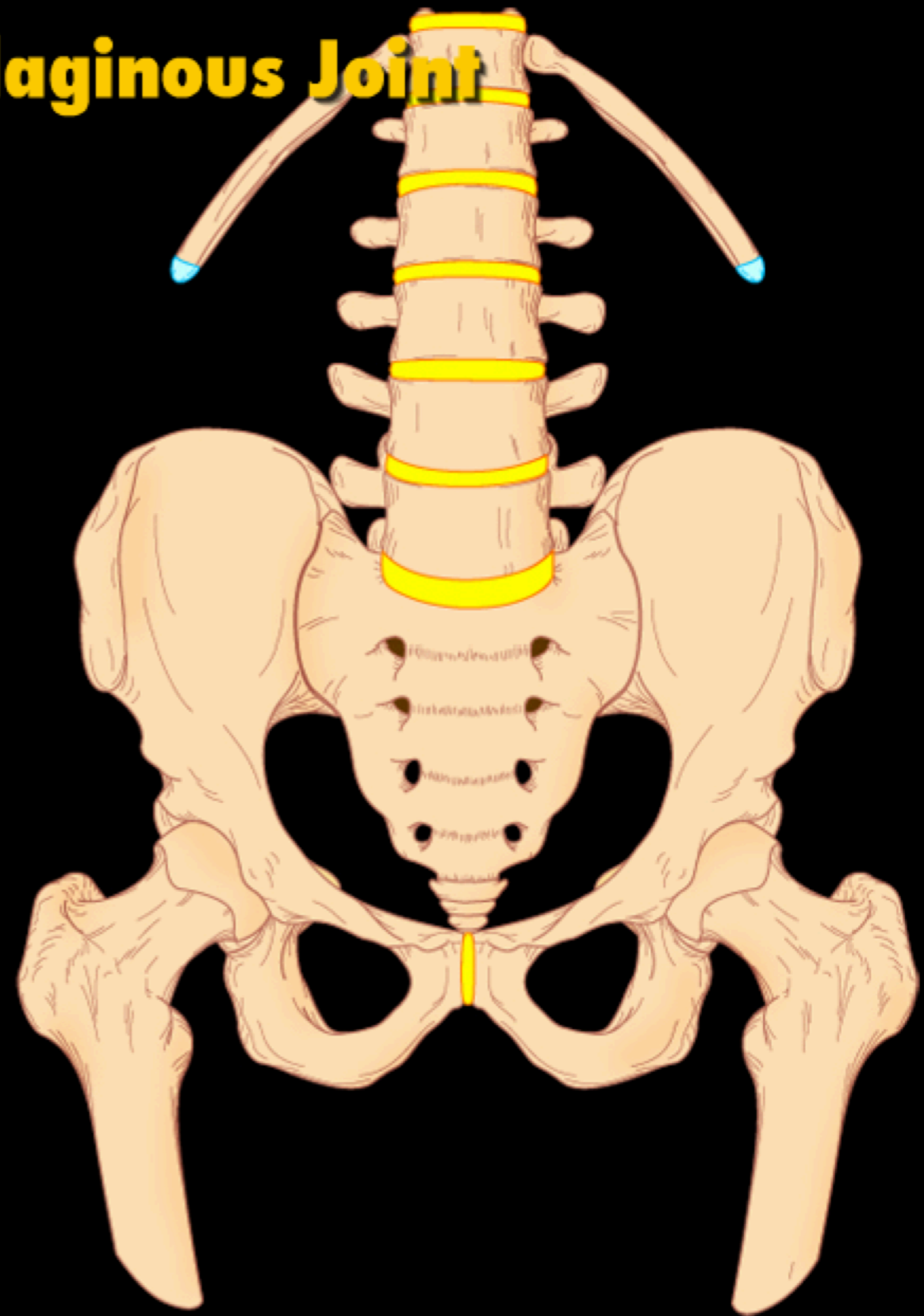
Epiphysial Cartilage or Primary Cartilaginous Joint



Arthrology

Cartilaginous Joints

Symphysis or Secondary Cartilaginous Joint



Arthrology


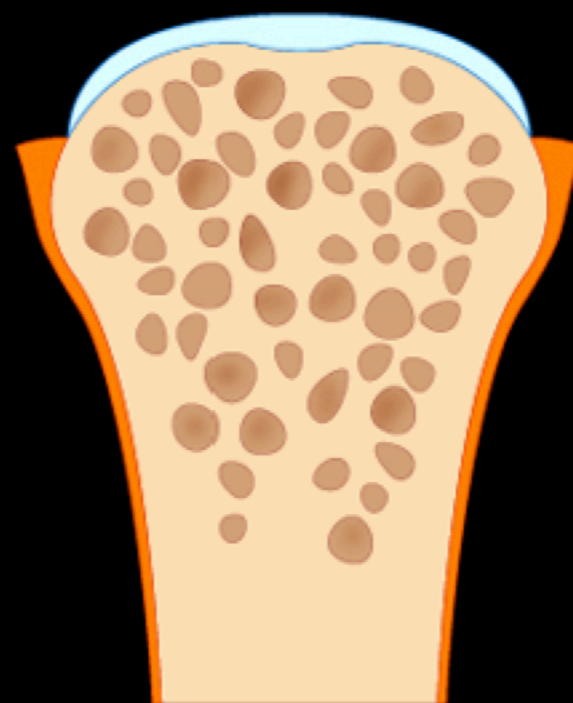
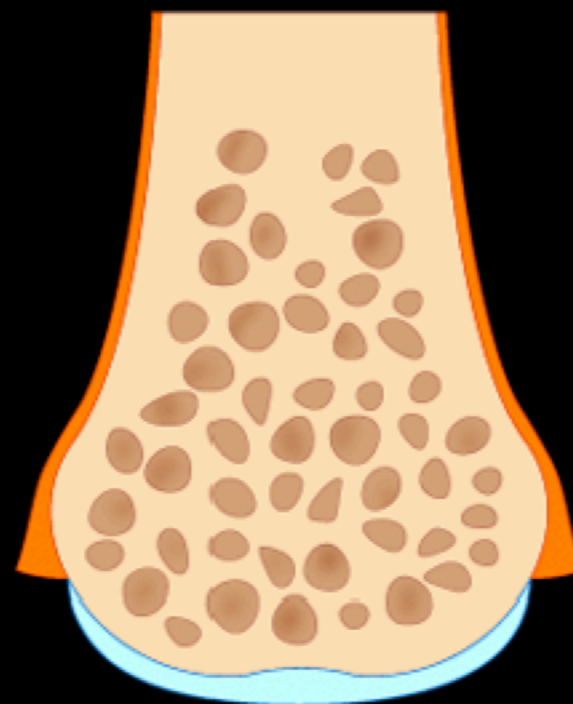
Synovial Joints

Review of Bone Anatomy

Compact bone surface

Periosteum

Articular cartilage

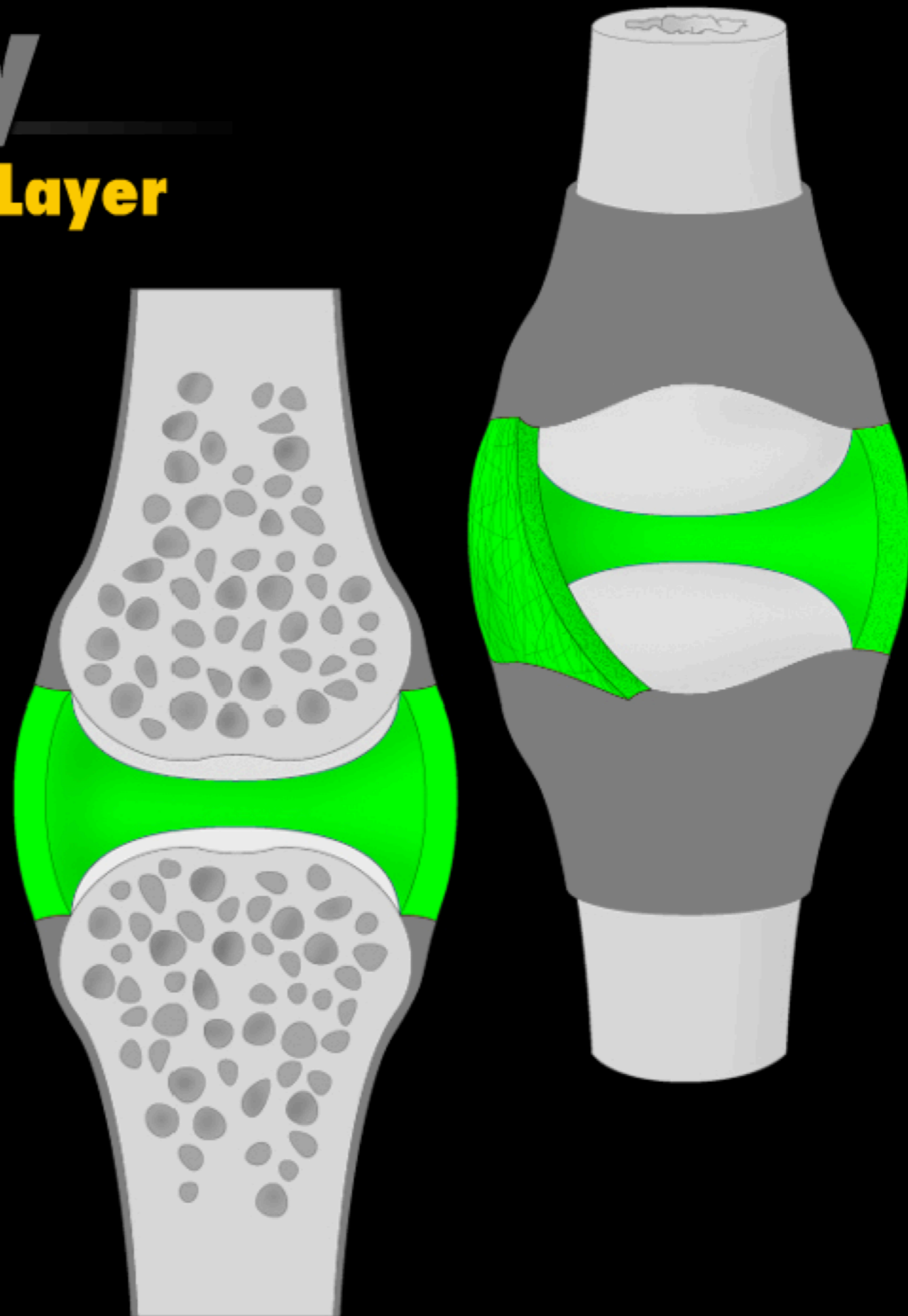


Arthrology

Synovial Joints

Layer One - External Layer

Fibrous membrane

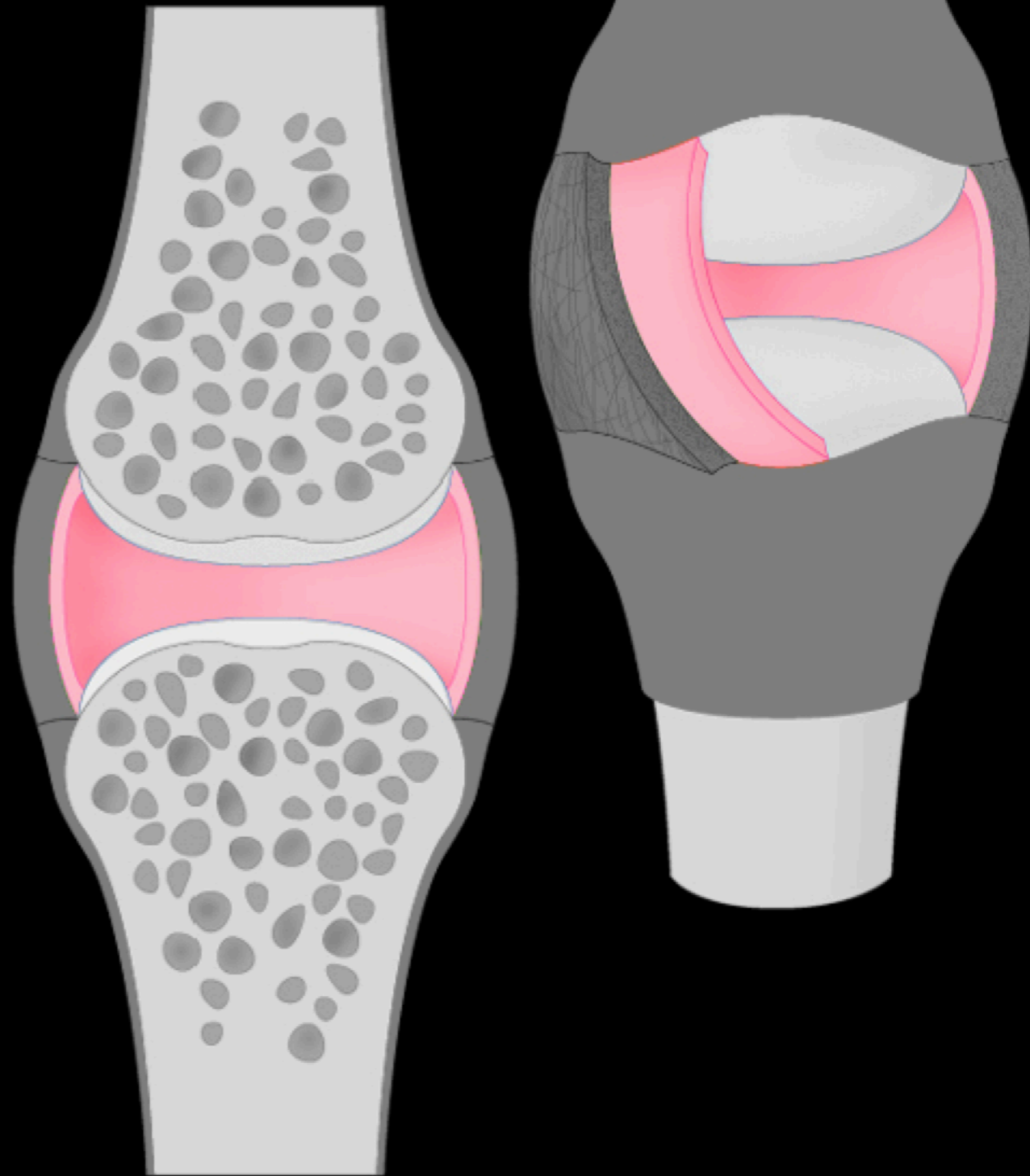


Arthrology

Synovial Joints

Layer Two - Internal Layer

Synovial membrane

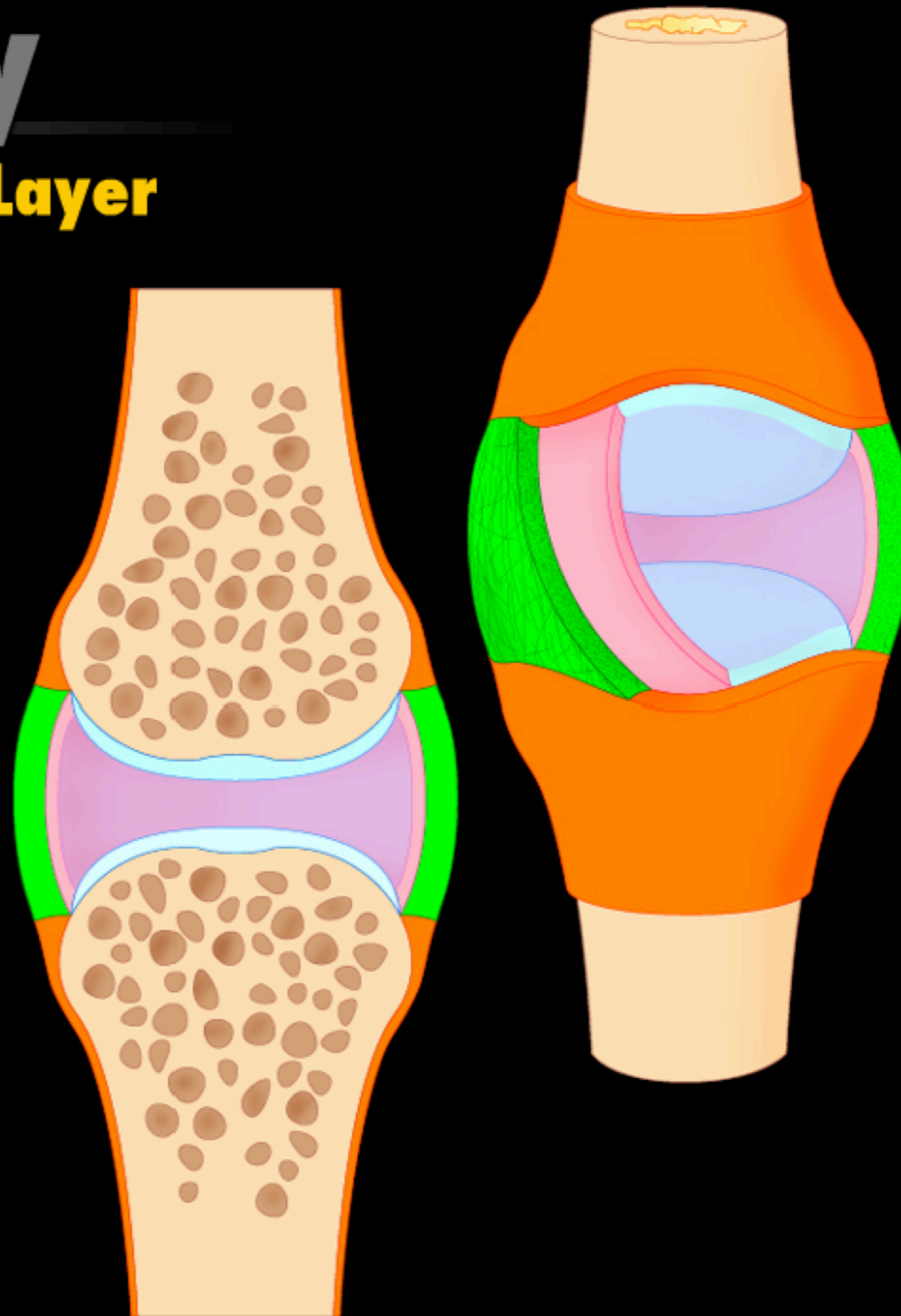


Arthrology

Synovial Joints

Layer Two - Internal Layer

Synovial fluid



Arthrology

Synovial Joints

Meniscus and Articular Disc

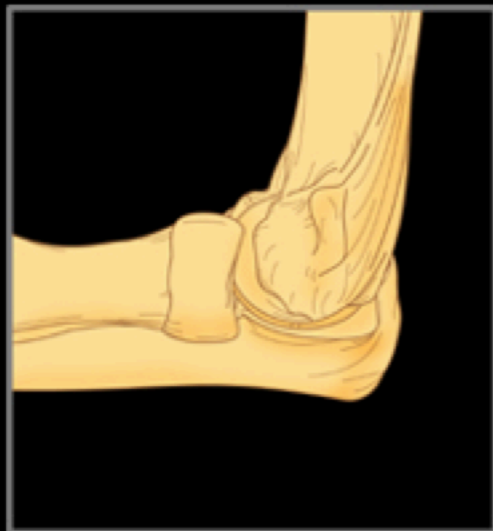Can you identify all the structures?



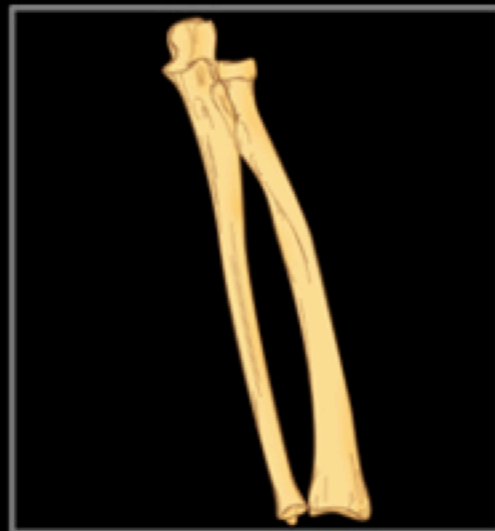Arthrology

Synovial Joints

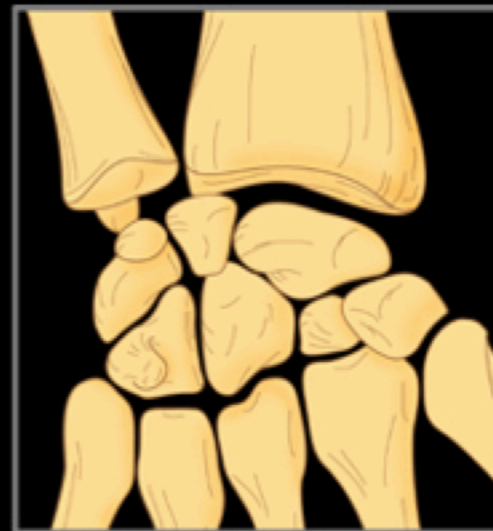Types of Synovial Joints



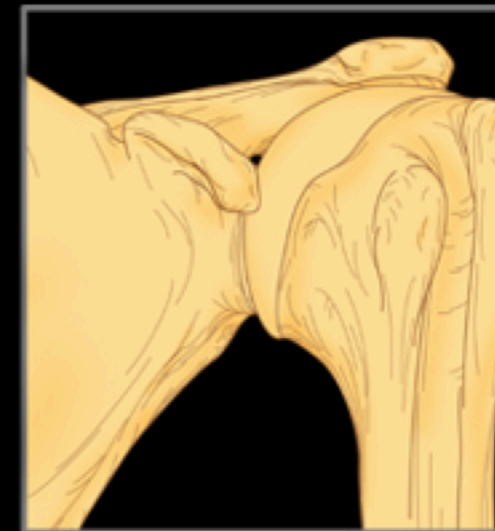Ginglymi joint



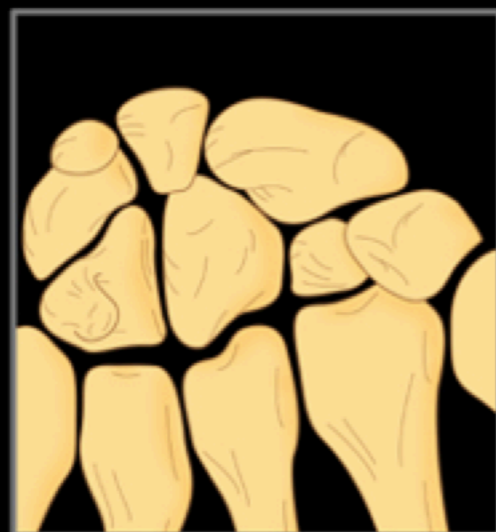Trochoid joint



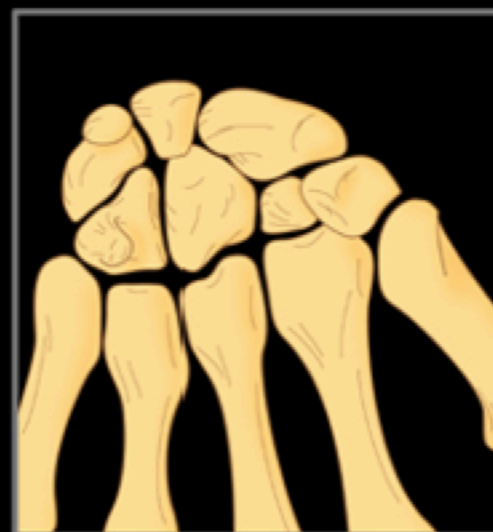Condylar joint



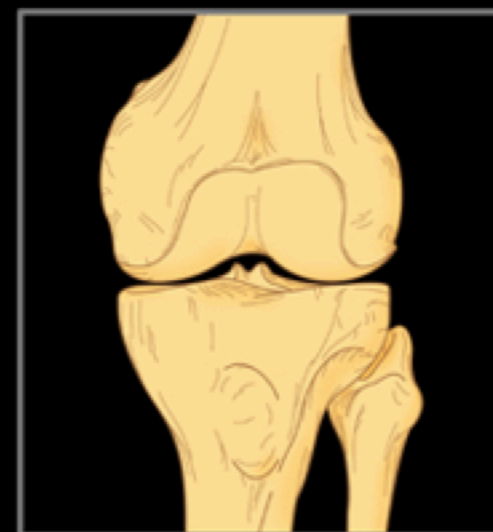Spheroidal joint



Plane joint



Sellar joint



Bicondylar joint

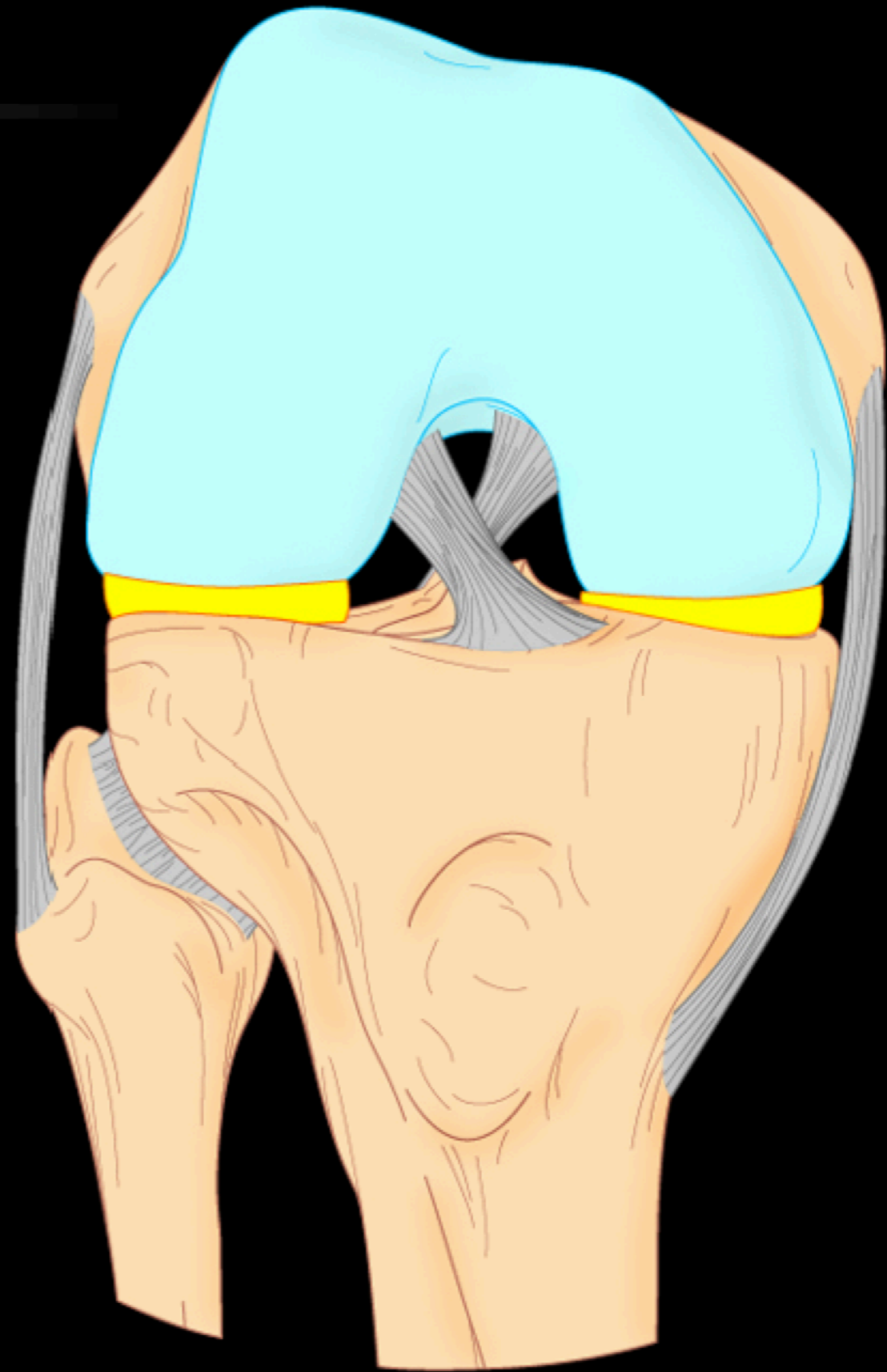
Ligaments Arthrology

Ligament Design

Definition


Structure

Relation to joints



Synovial Bursa

Fibrous membrane

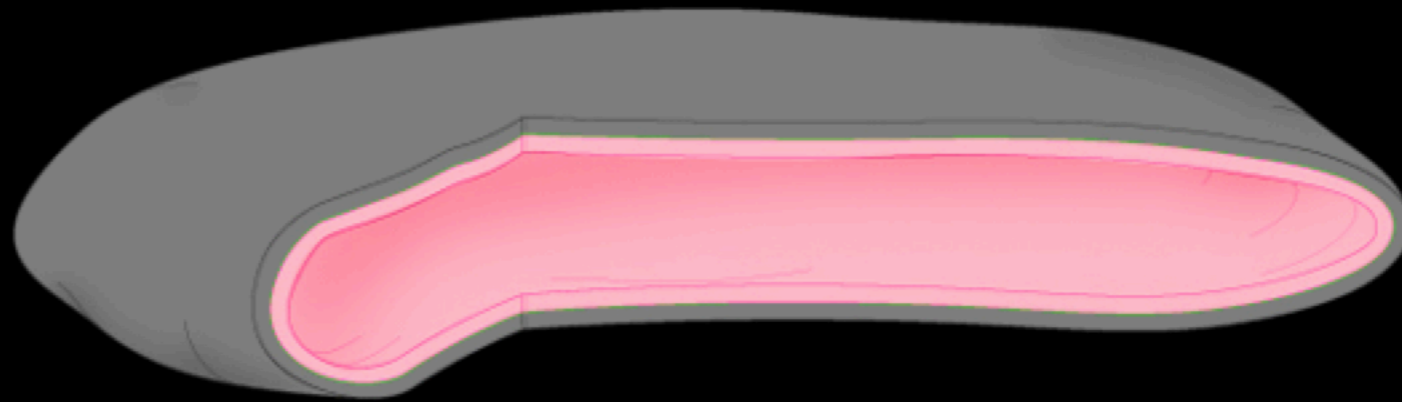


Arthrology

Other Synovial Structures

Synovial Bursa

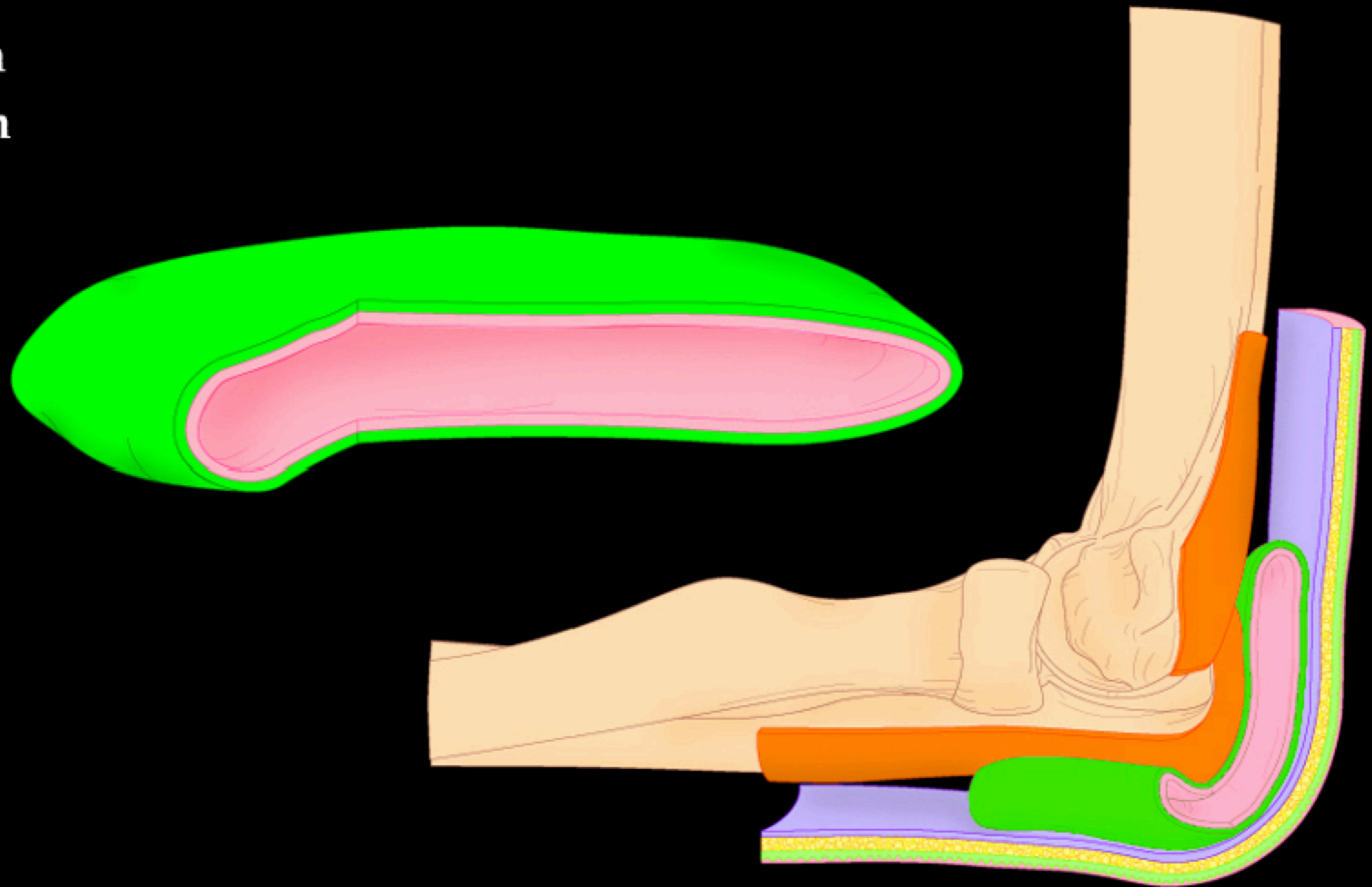
Synovial membrane



Synovial Bursa


Location

Function



Synovial Sheaths

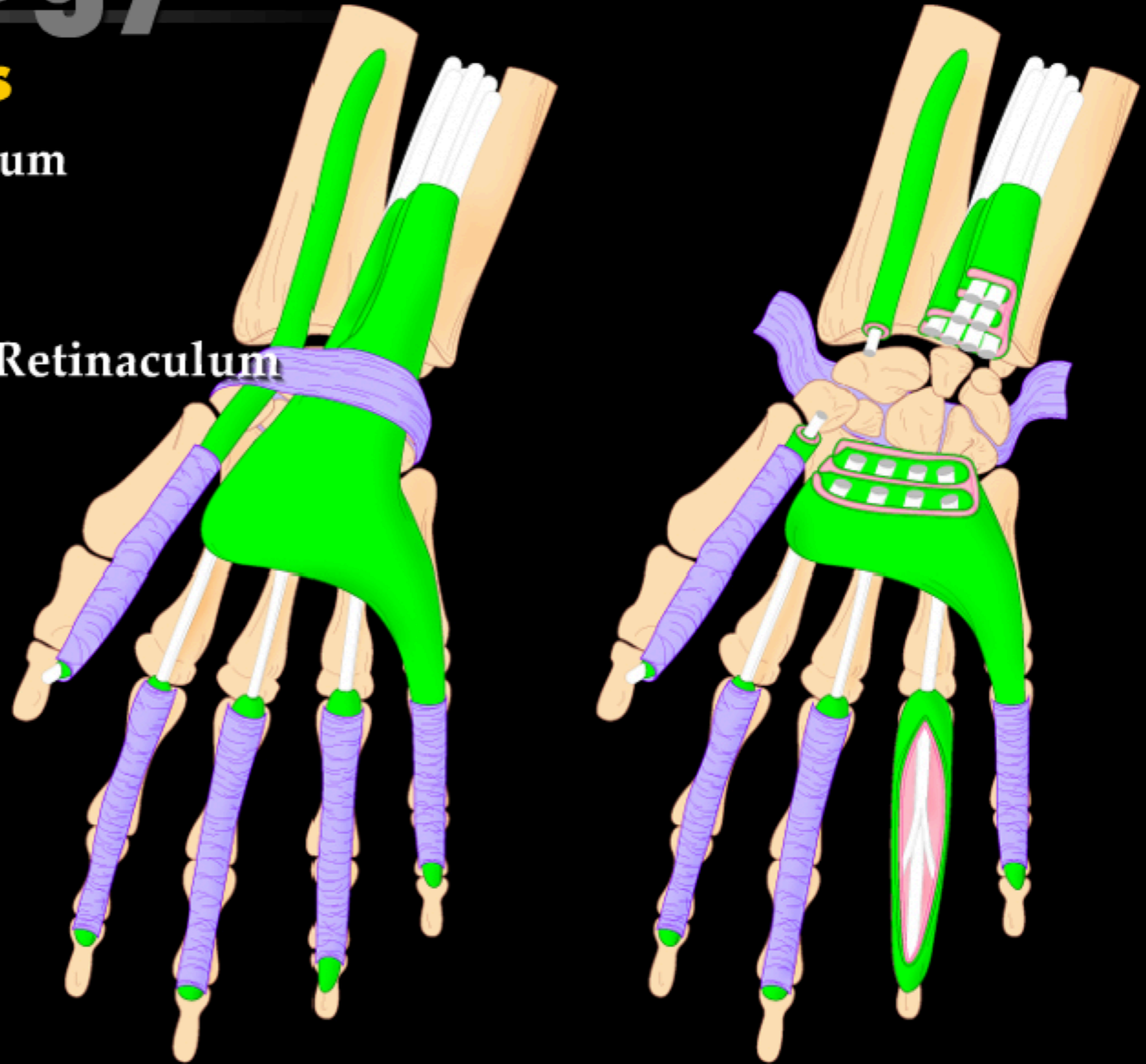
Modified bursa



Synovial Sheaths

Relation to retinaculum

Retinaculum



Synovial Sheaths

Location

Function

