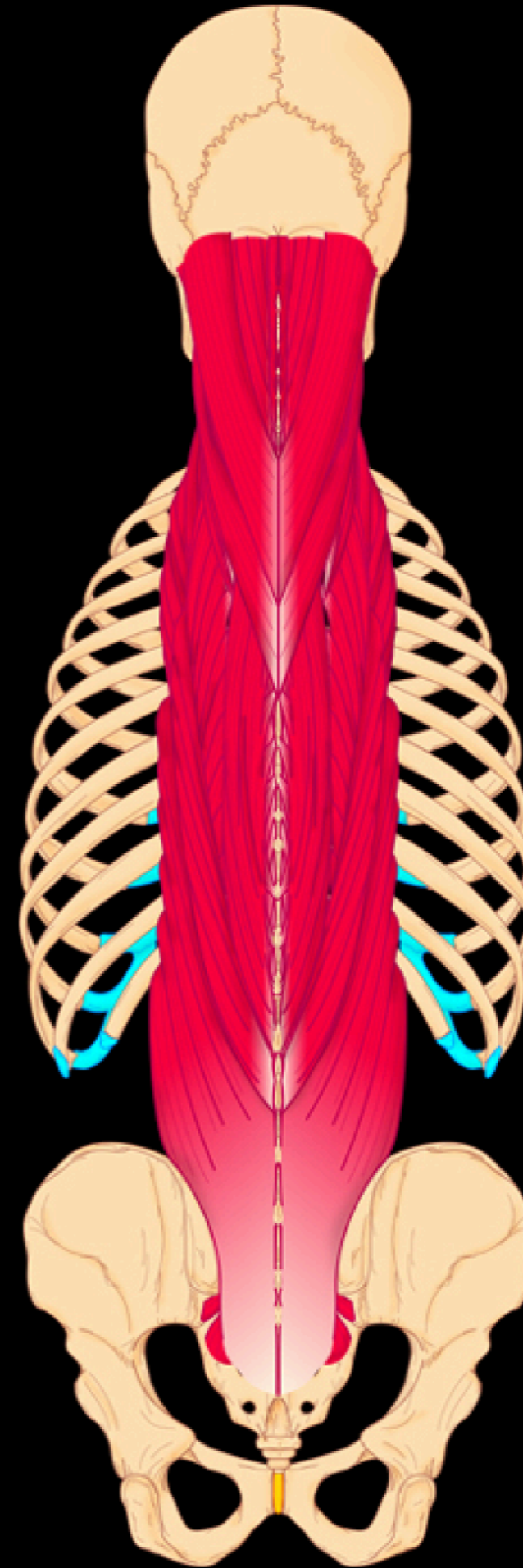


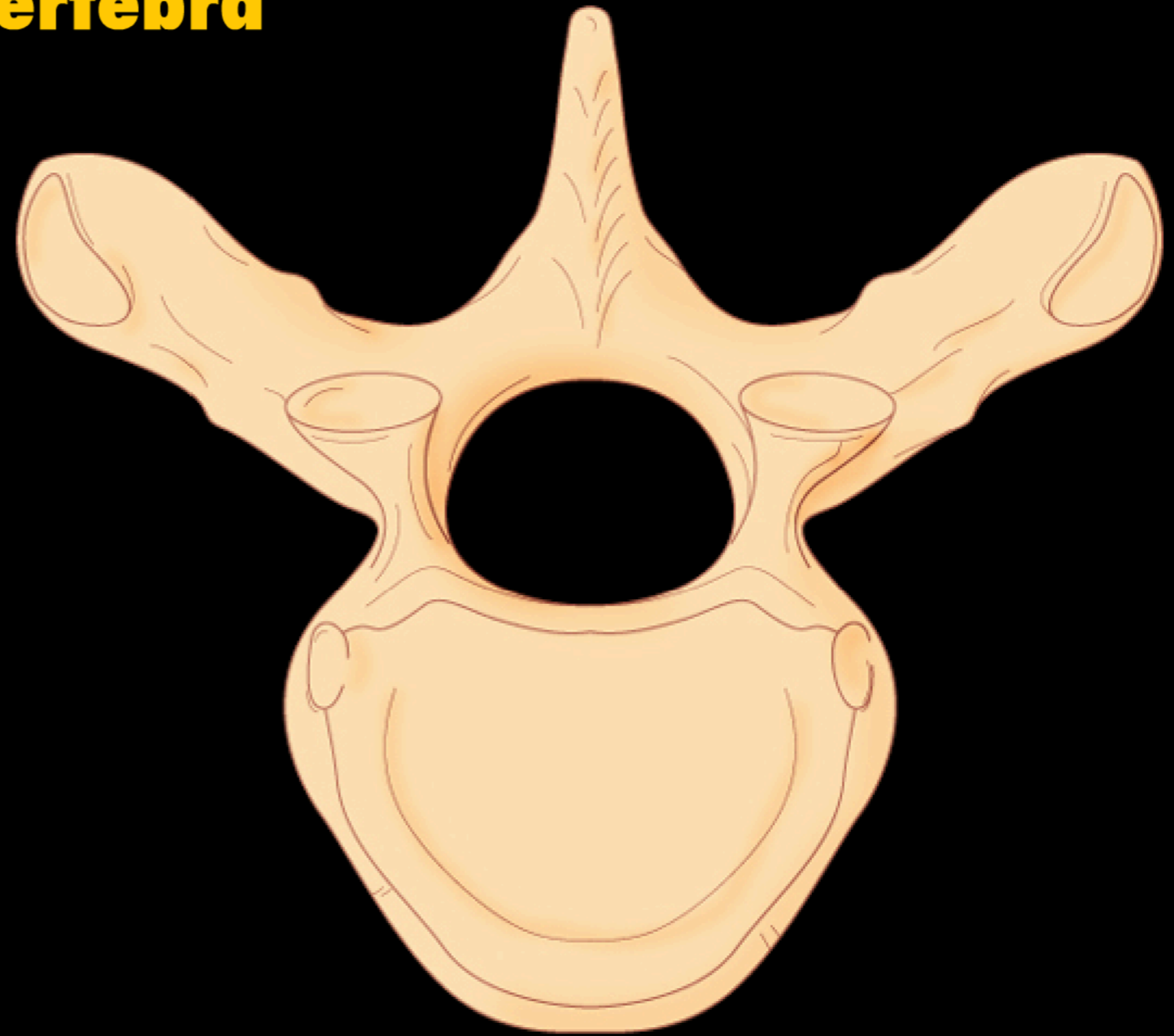
Back Anatomy



Back Anatomy

Review of Vertebral Anatomy

Principal Parts of a Vertebra

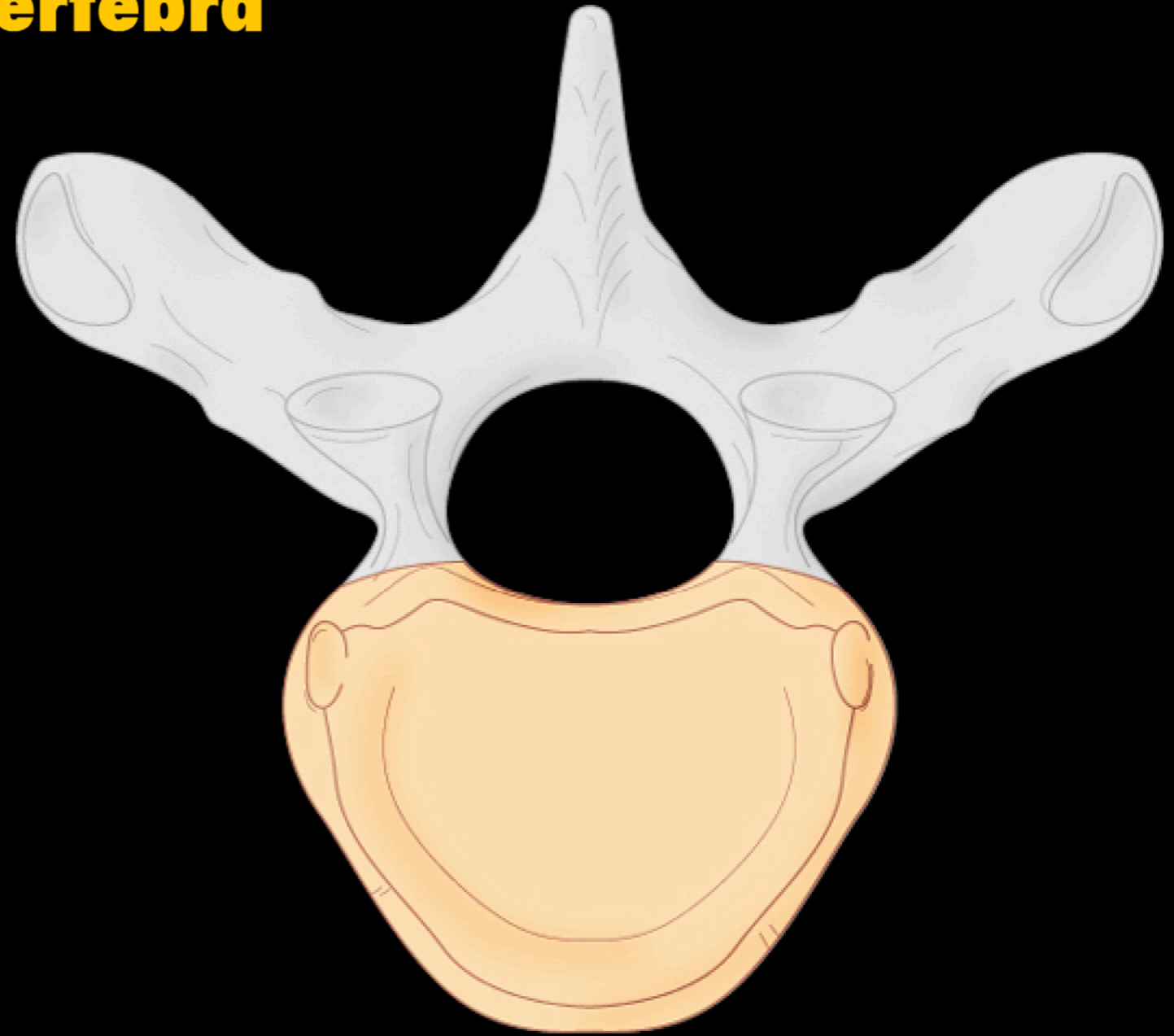


Back Anatomy

Review of Vertebral Anatomy

Principal Parts of a Vertebra

Vertebral body

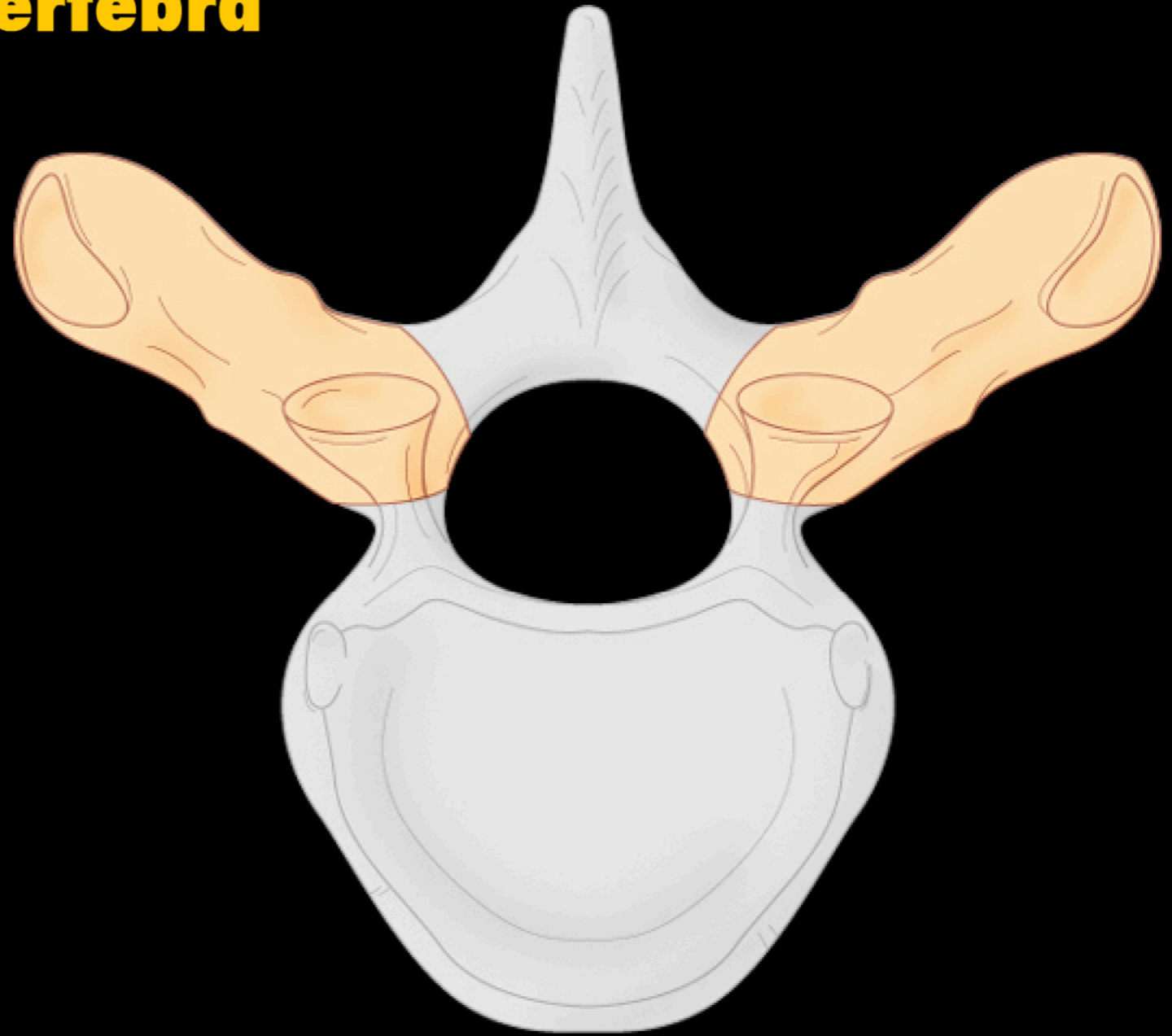


Back Anatomy

Review of Vertebral Anatomy

Principal Parts of a Vertebra

Transverse process

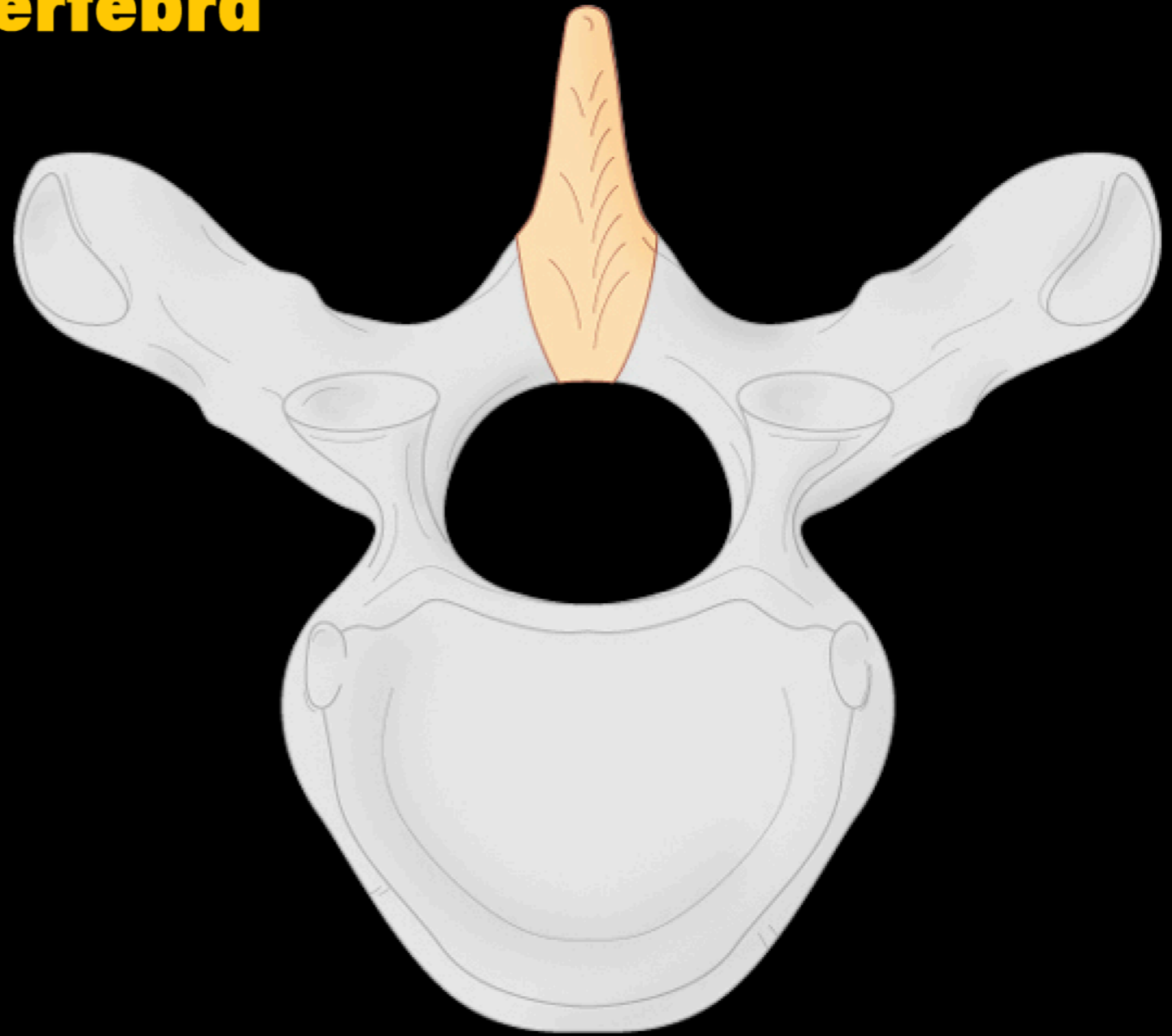


Back Anatomy

Review of Vertebral Anatomy

Principal Parts of a Vertebra

Spinous process

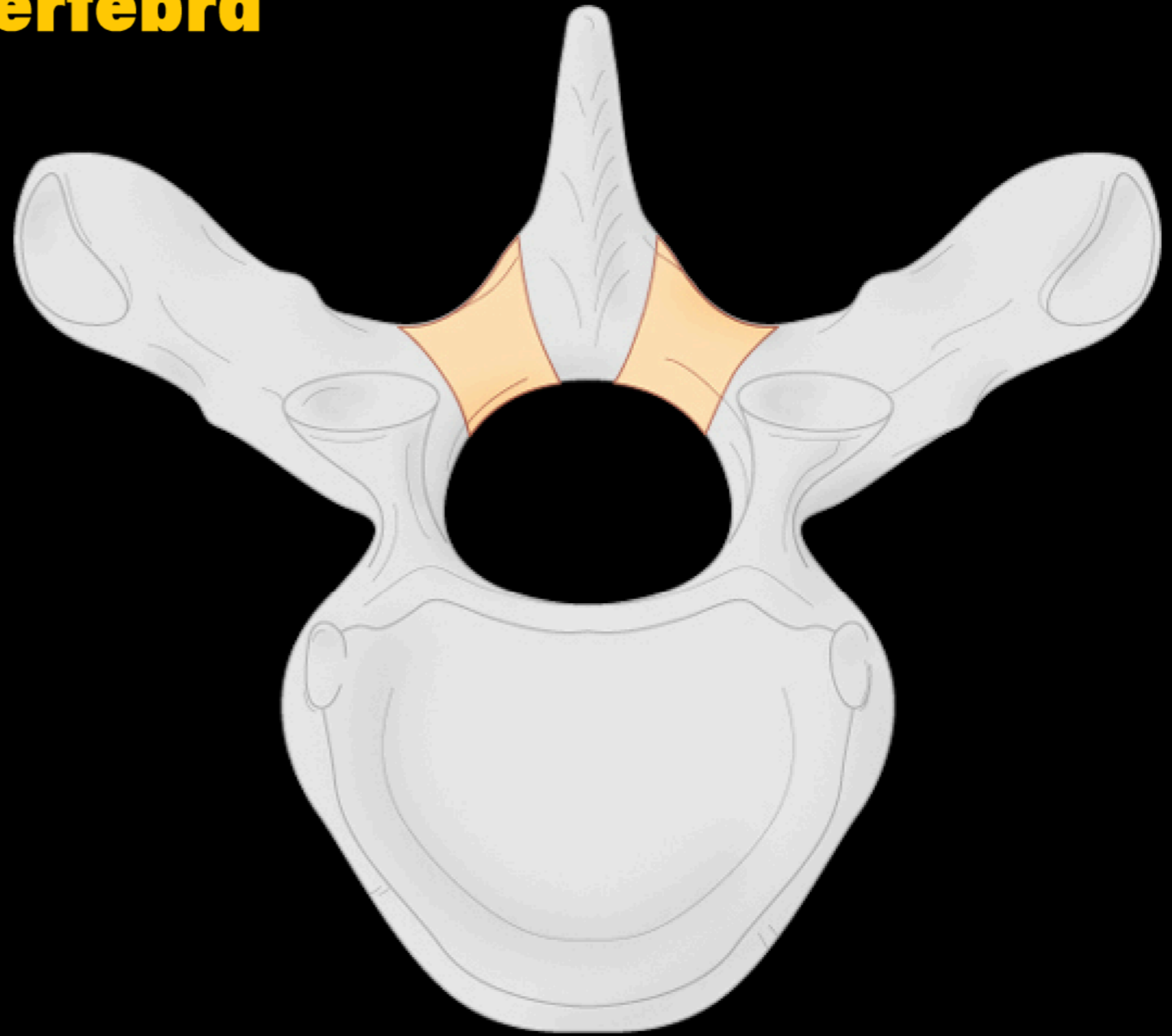


Back Anatomy

Review of Vertebral Anatomy

Principal Parts of a Vertebra

Lamina

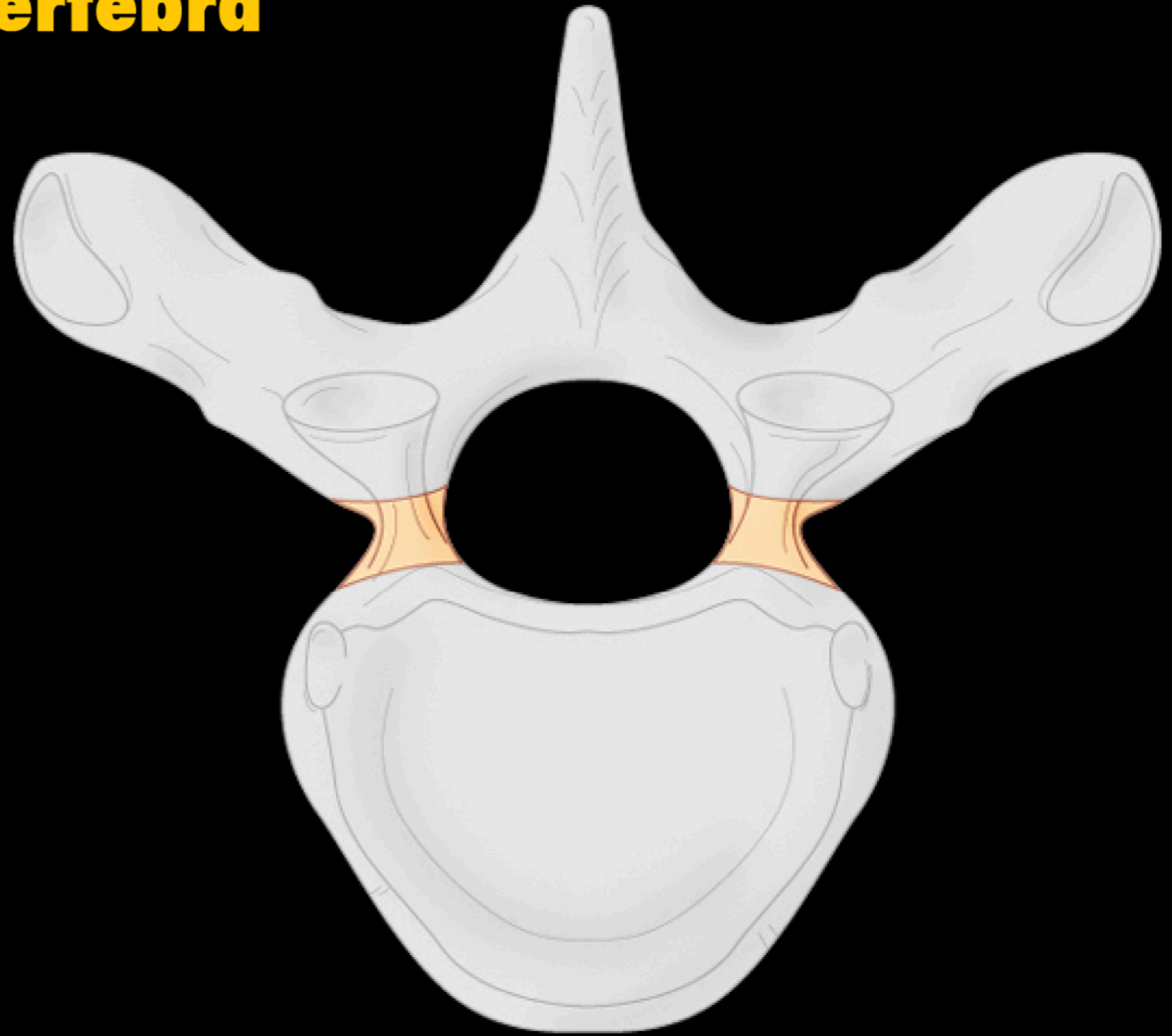


Back Anatomy

Review of Vertebral Anatomy

Principal Parts of a Vertebra

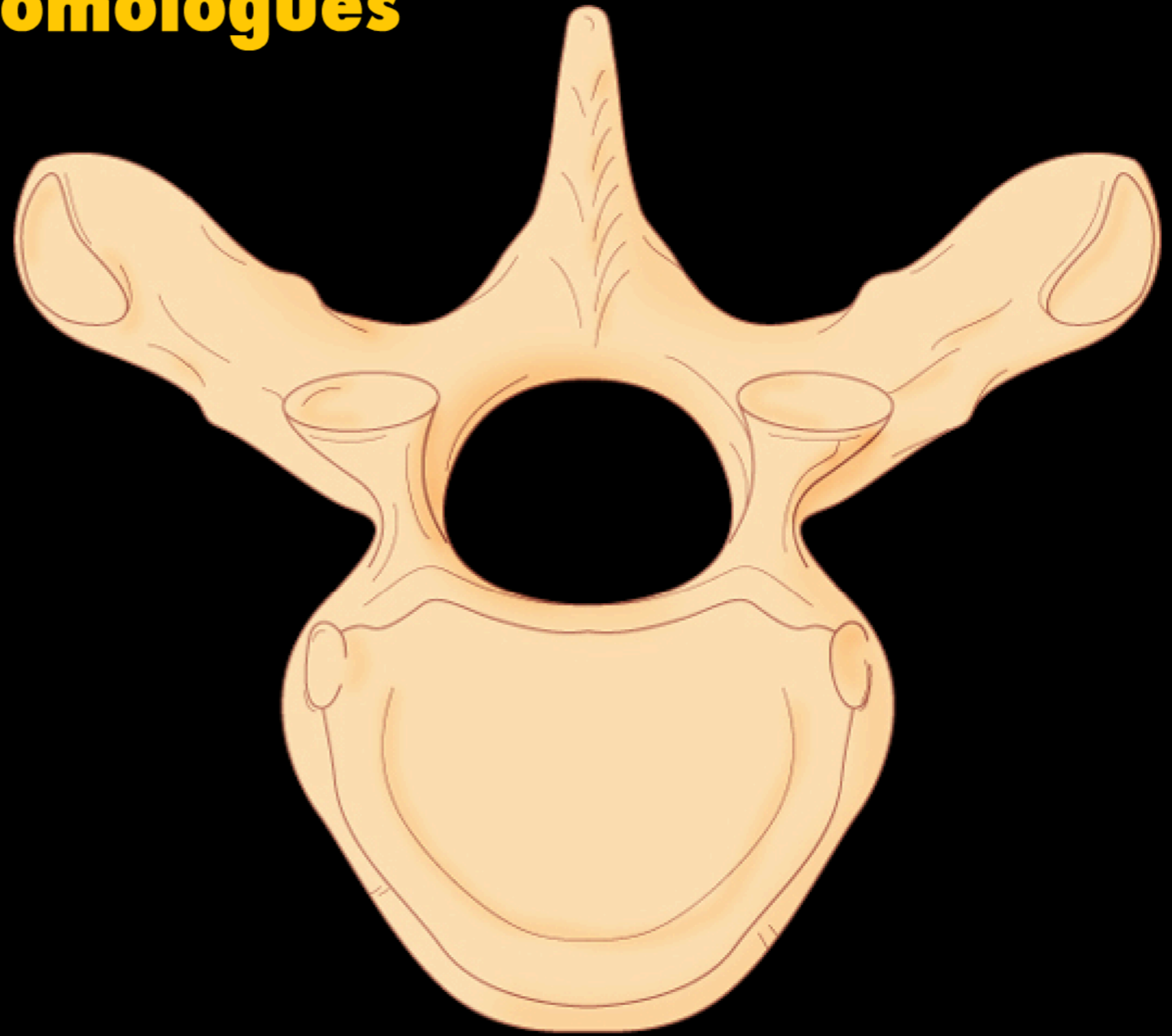
Pedicle



Back Anatomy

Vertebral Development


Vertebrae as Serial Homologues



Back Anatomy

Vertebral Development

Vertebral Osteogenesis




Back Anatomy

Vertebral Development

Vertebral Osteogenesis

Vertebral body

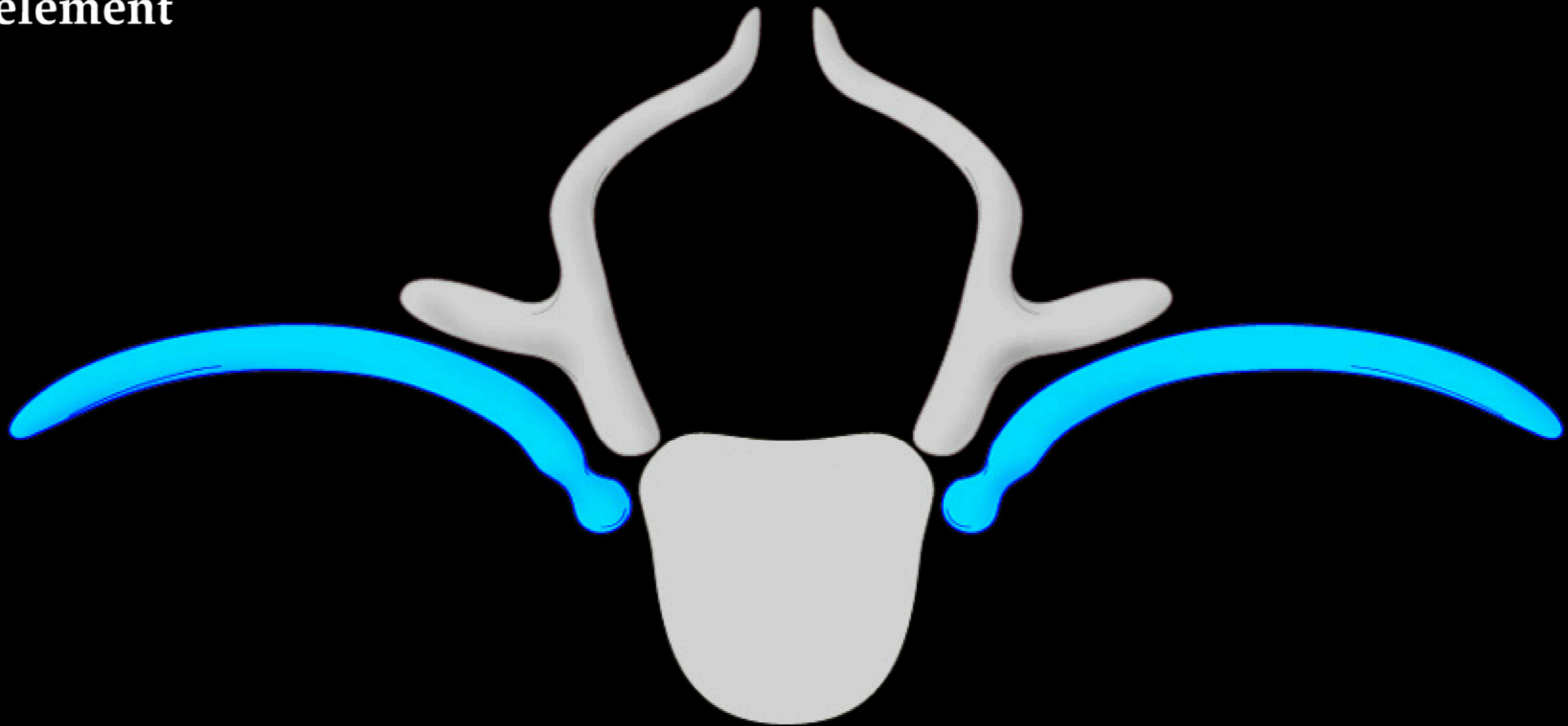


Back Anatomy

Vertebral Development

Vertebral Osteogenesis

Costal element



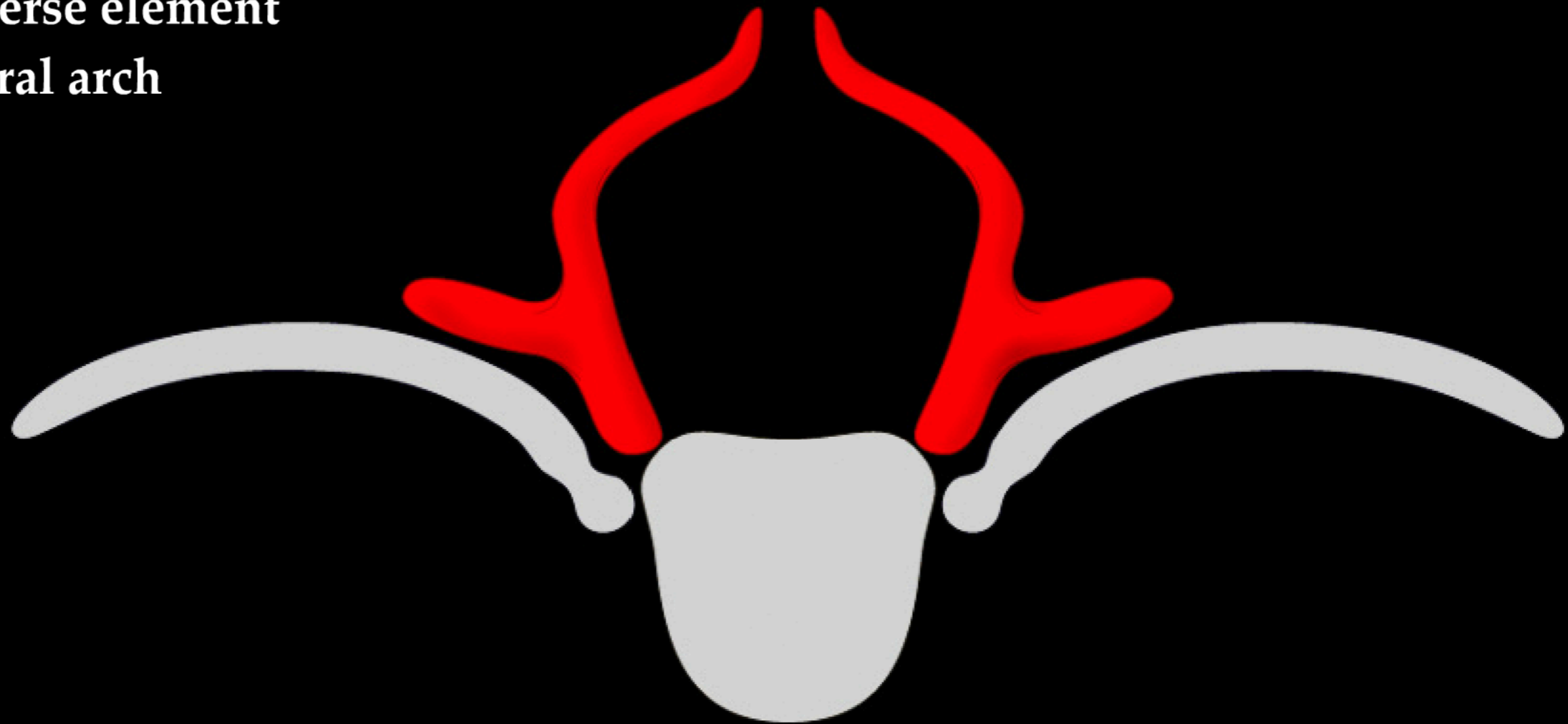
Back Anatomy

Vertebral Development

Vertebral Osteogenesis

Transverse element

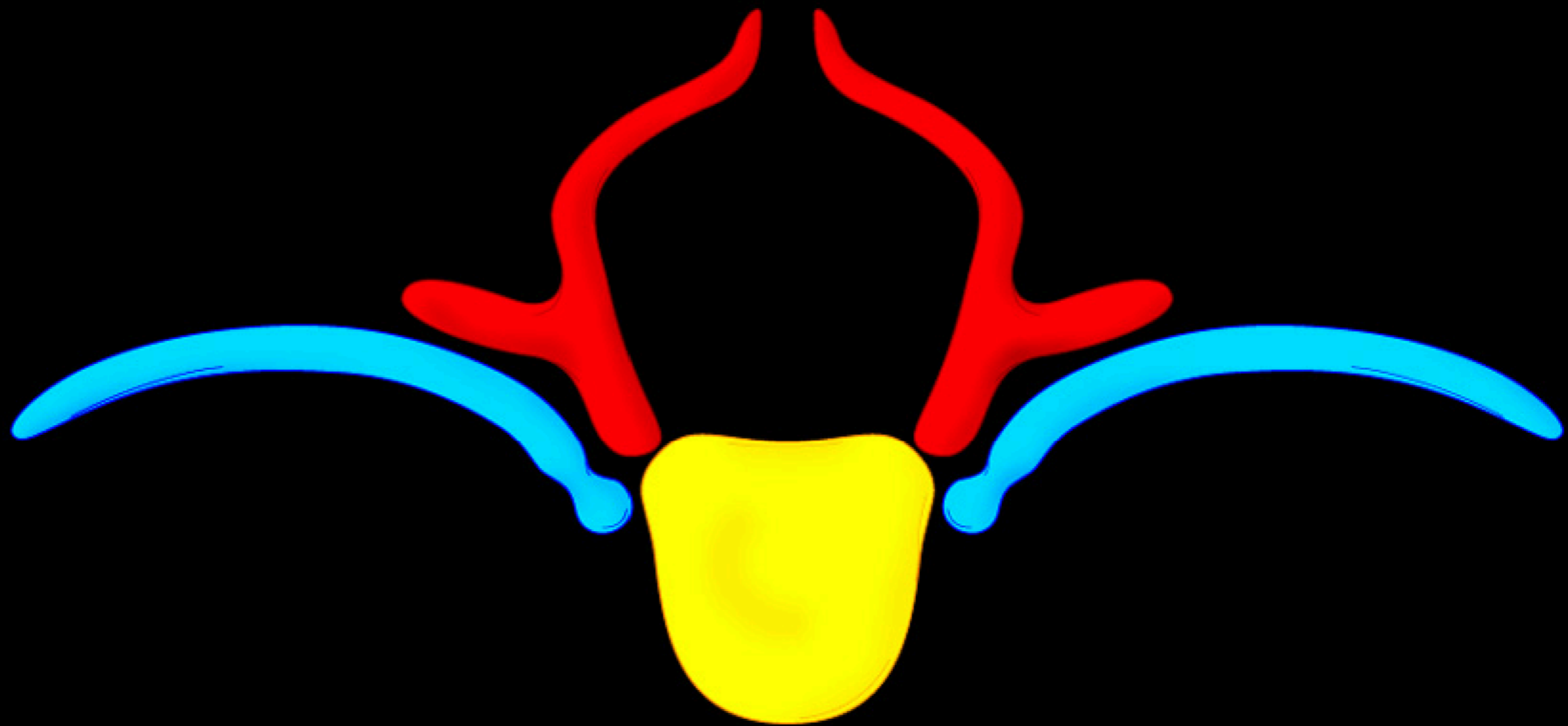
Vertebral arch



Back Anatomy

Vertebral Development

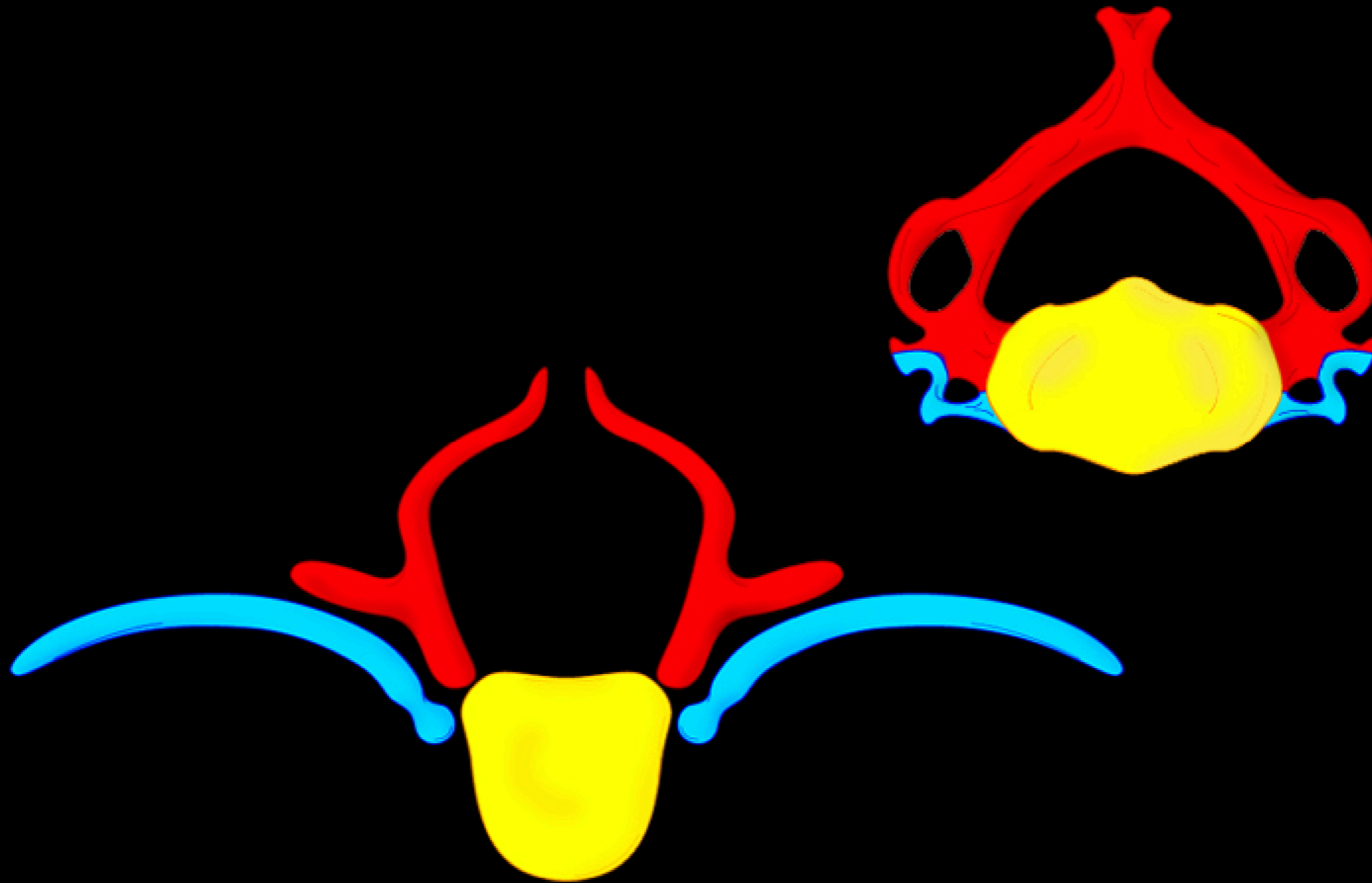
Vertebral Osteogenesis



Back Anatomy

Results of Vertebral Development

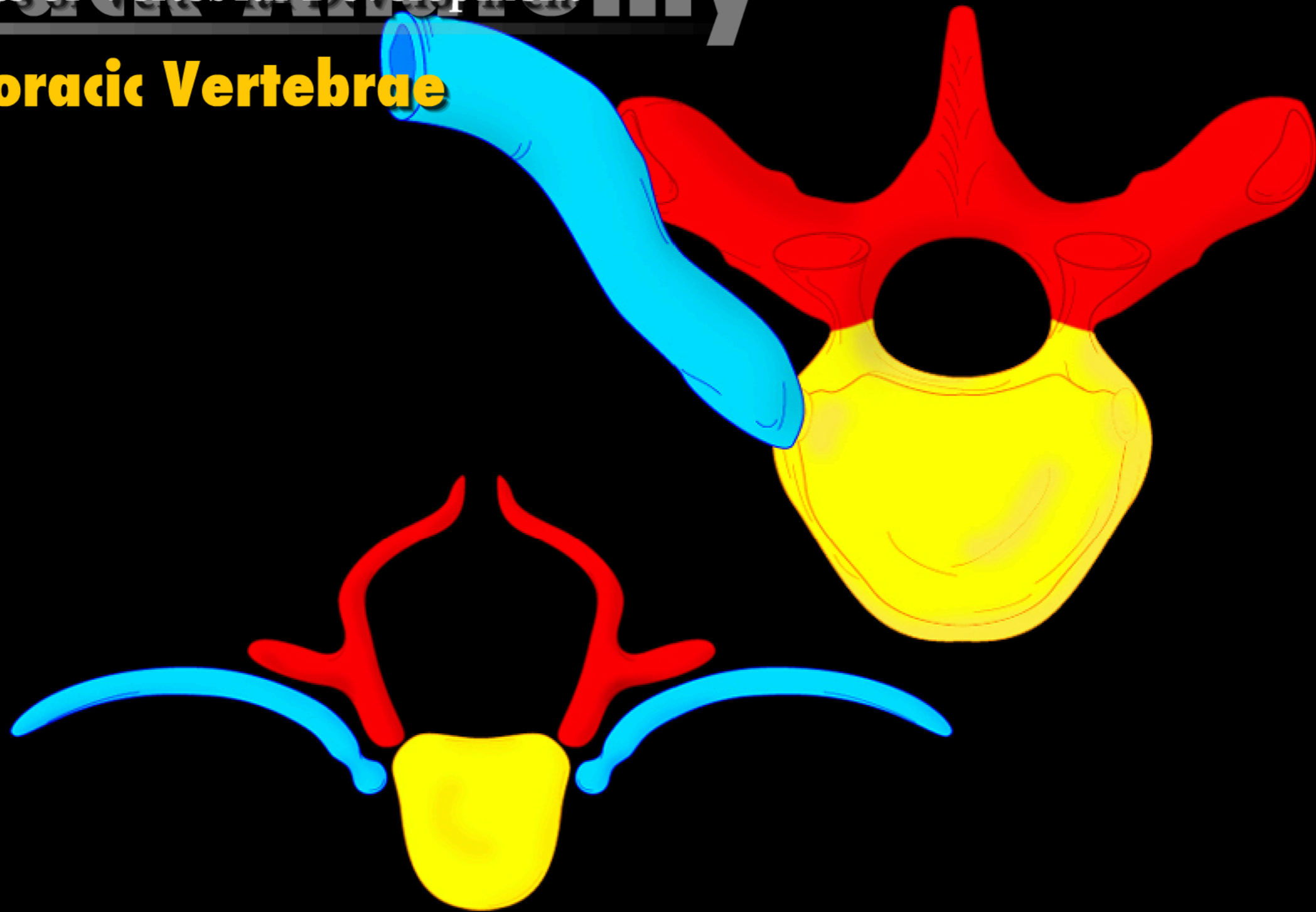
Cervical Vertebrae



Back Anatomy

Results of Vertebral Development

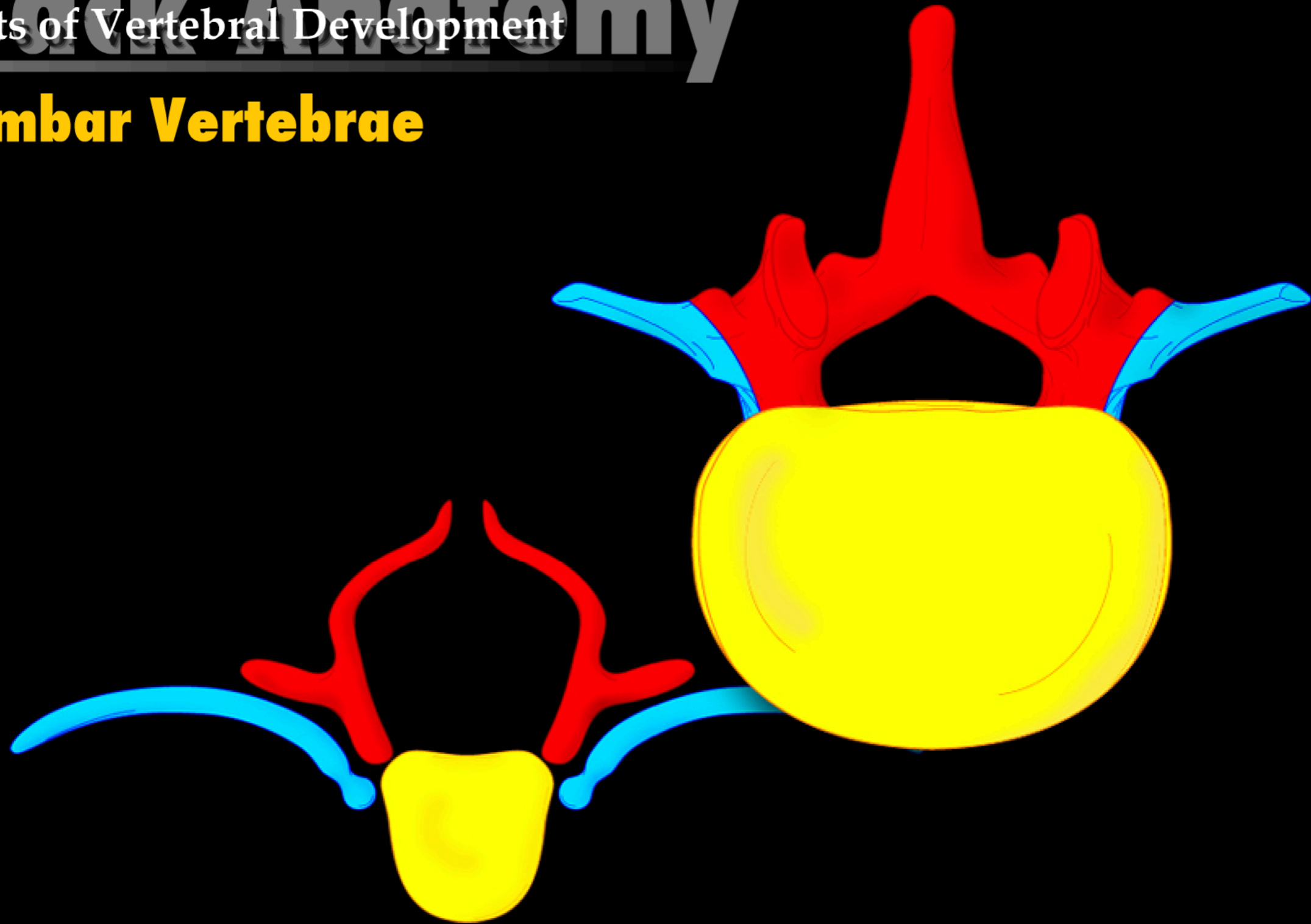
Thoracic Vertebrae



Back Anatomy

Results of Vertebral Development

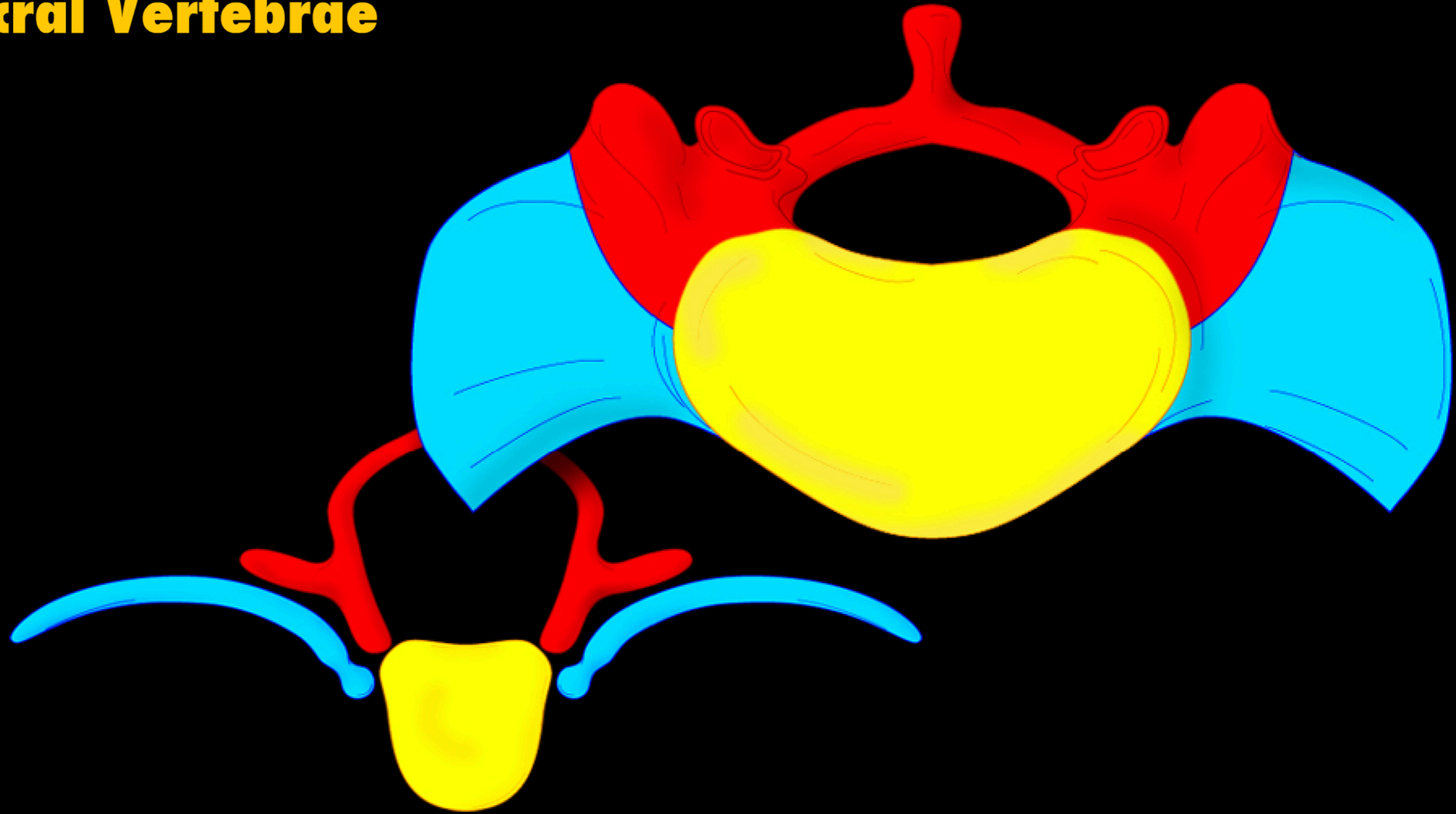
Lumbar Vertebrae



Back Anatomy

Results of Vertebral Development

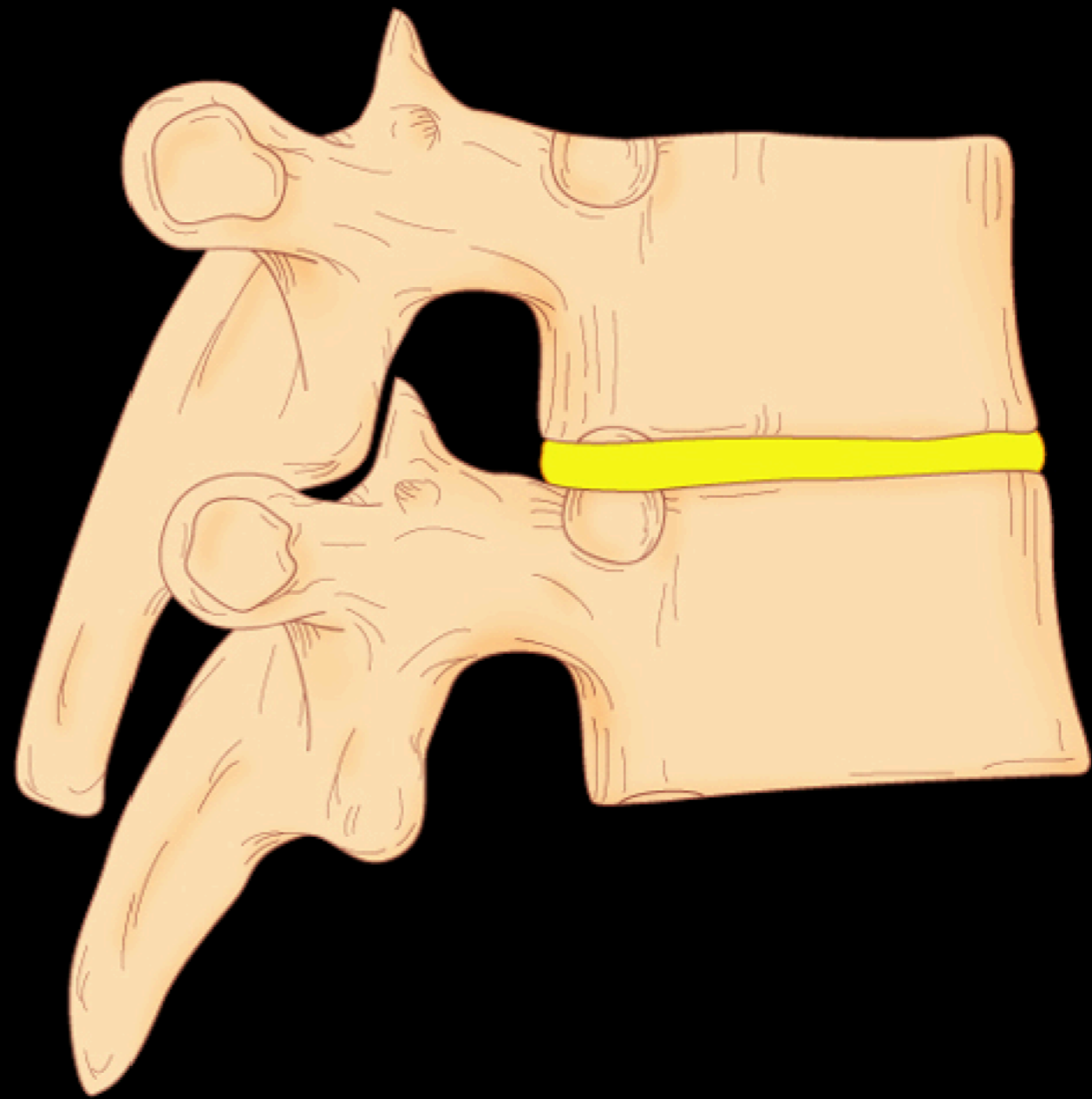
Sacral Vertebrae



Back Anatomy

Vertebral Joints and Ligaments

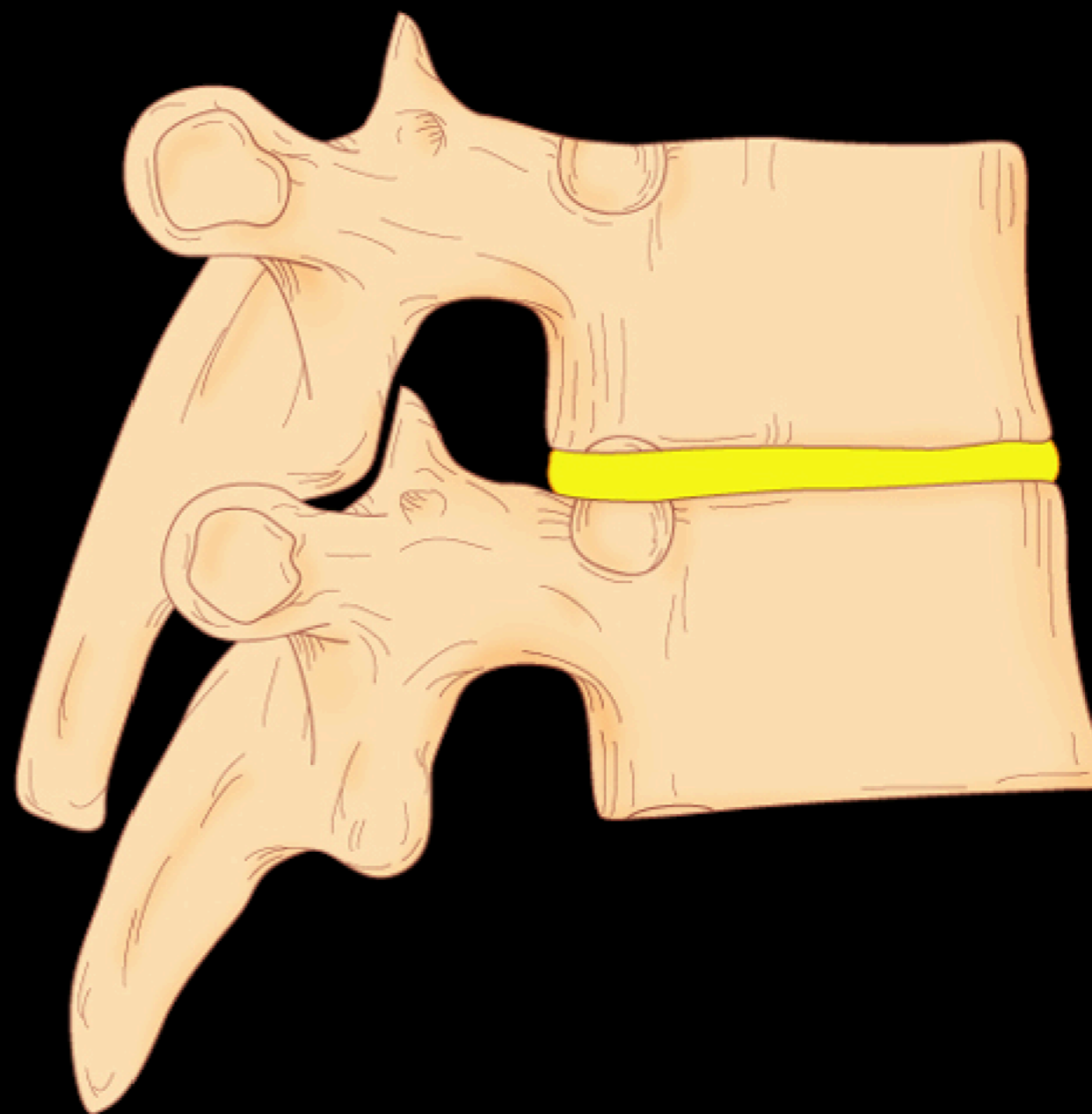
Cartilaginous Joints



Back Anatomy

Vertebral Joints and Ligaments

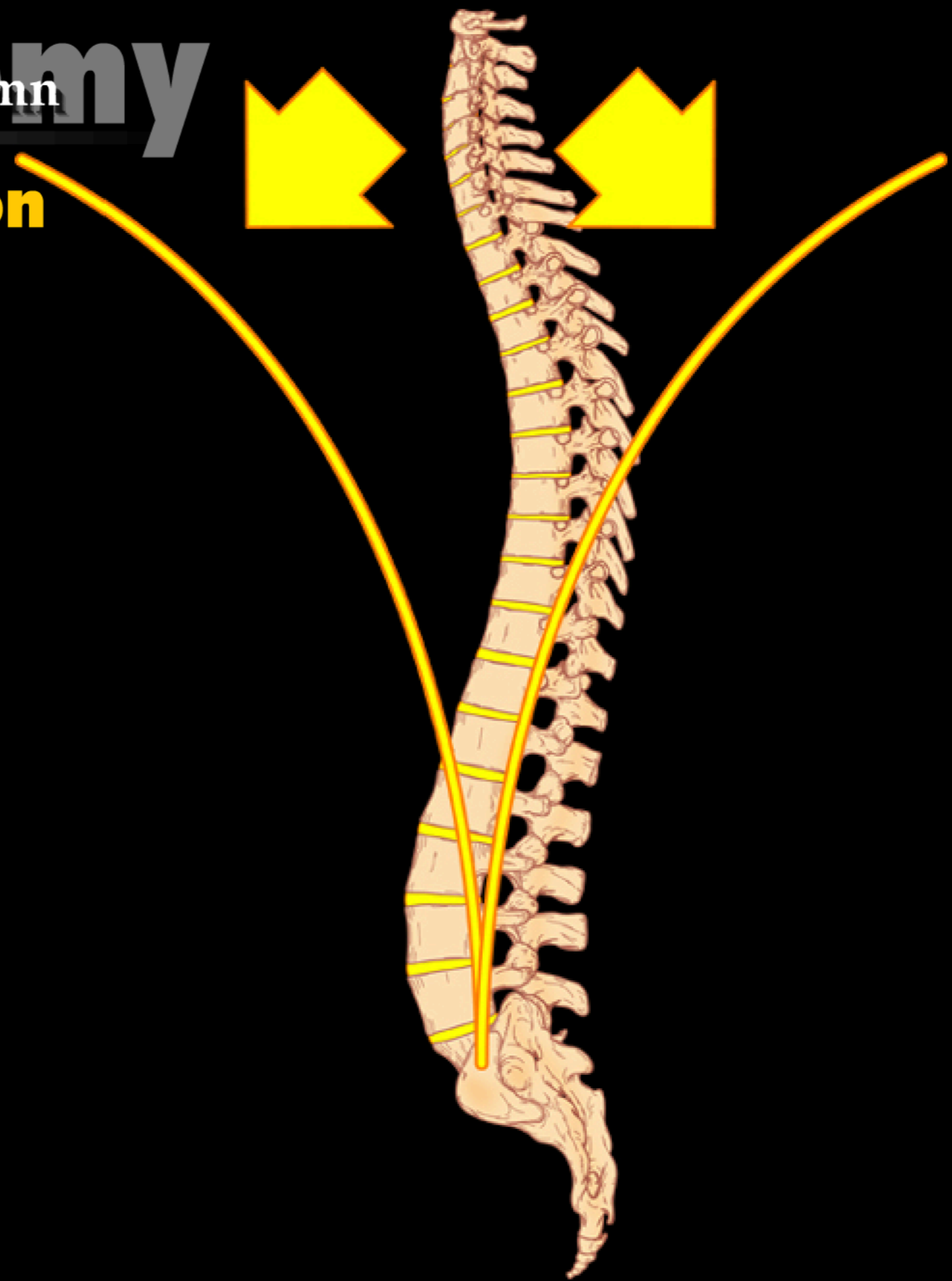Synovial Joints



Back Anatomy

Movements of the Vertebral Column

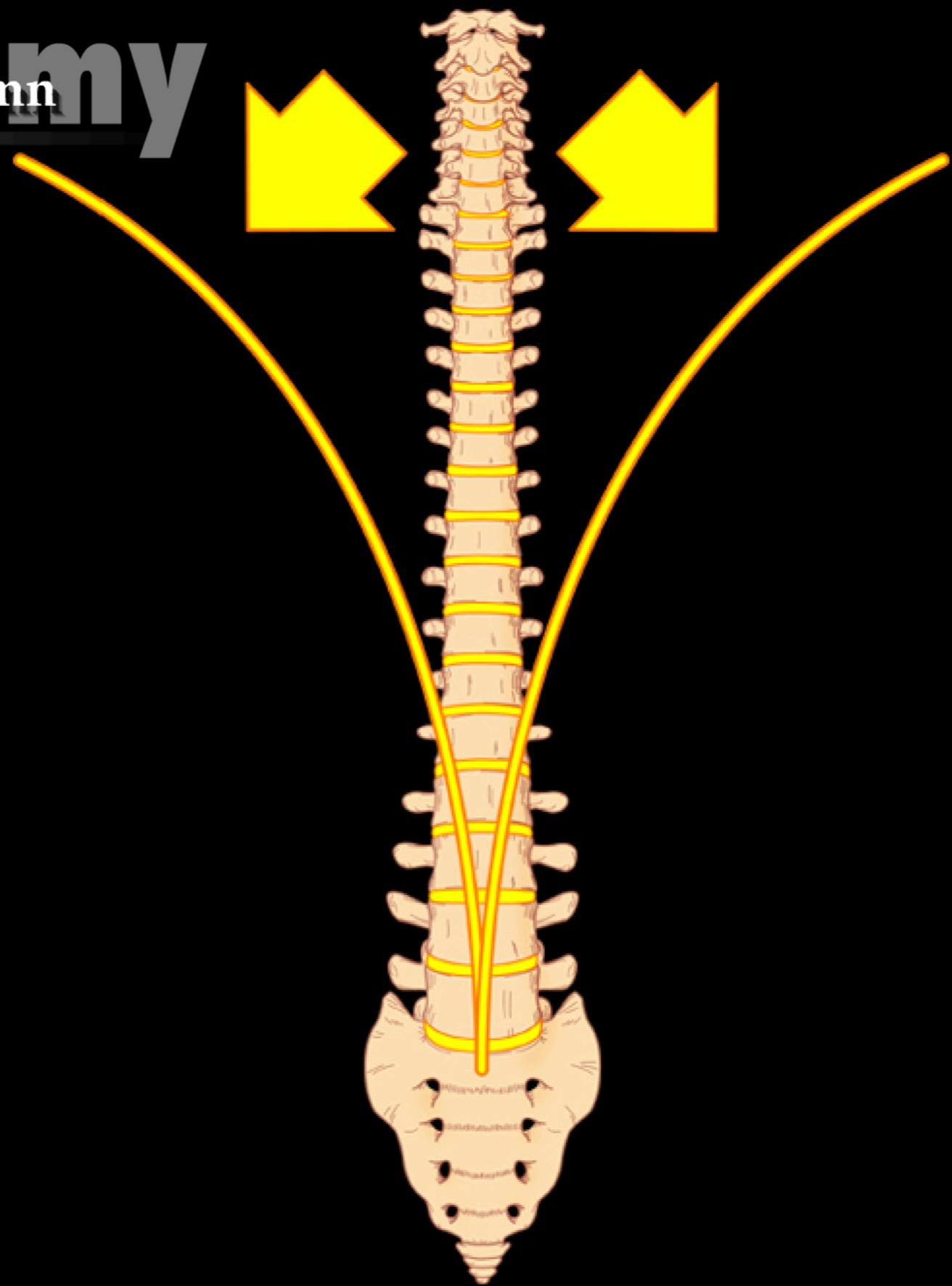
Extension versus Flexion



Back Anatomy

Movements of the Vertebral Column

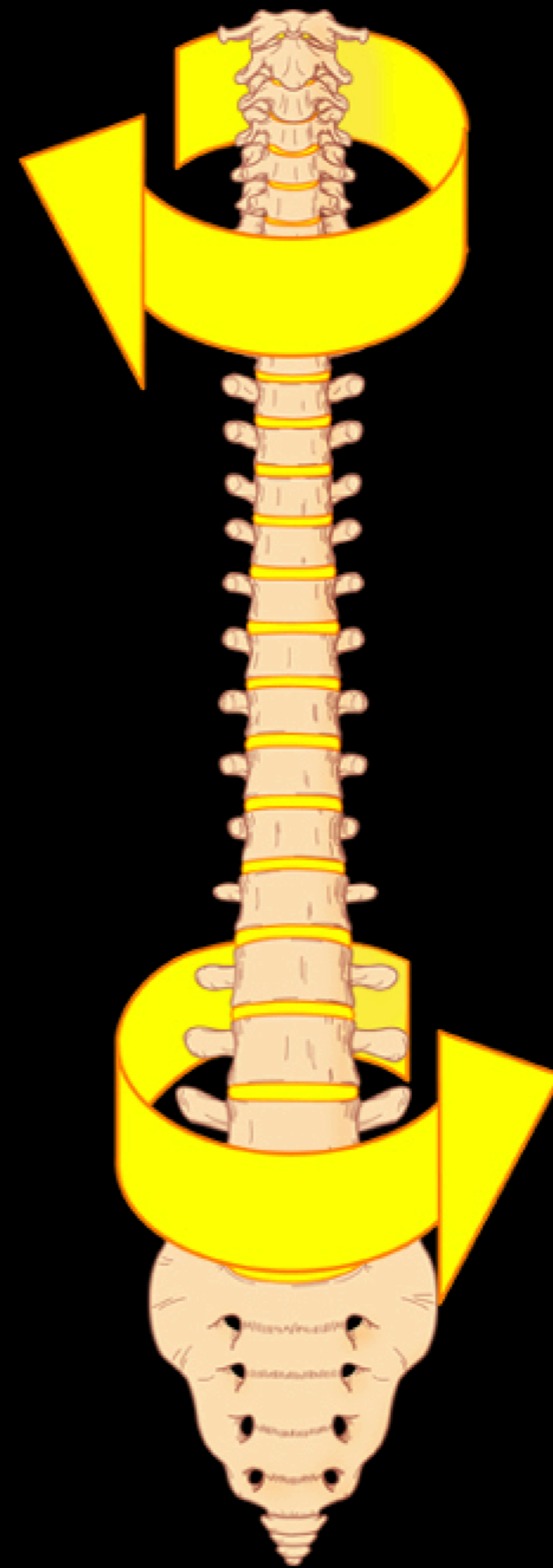
Lateral Flexion



Back Anatomy

Movements of the Vertebral Column

Rotation



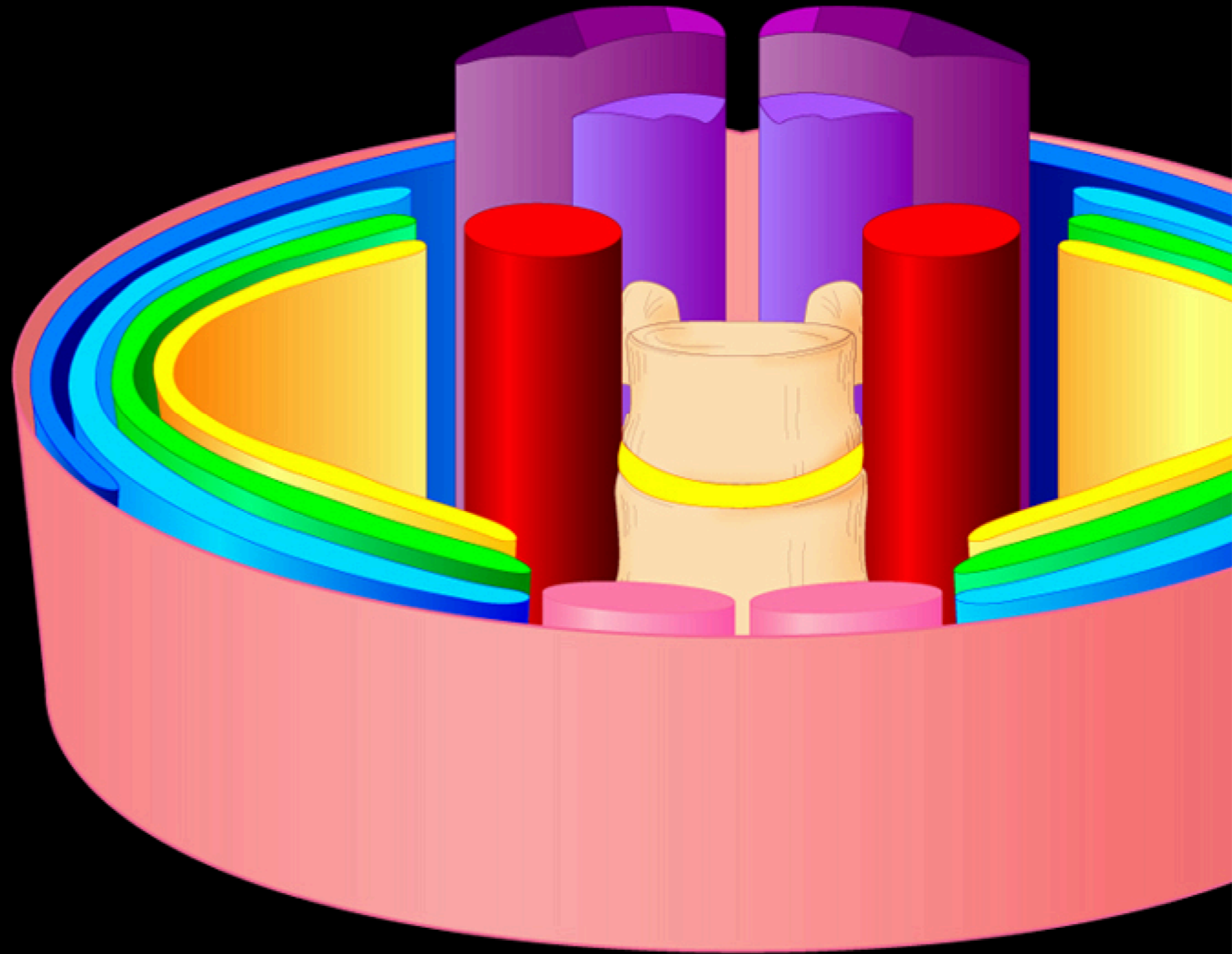
Back Anatomy

Review of the Pattern

Finally, the Epaxial Muscles

Superficial group

Deep group



Back Anatomy

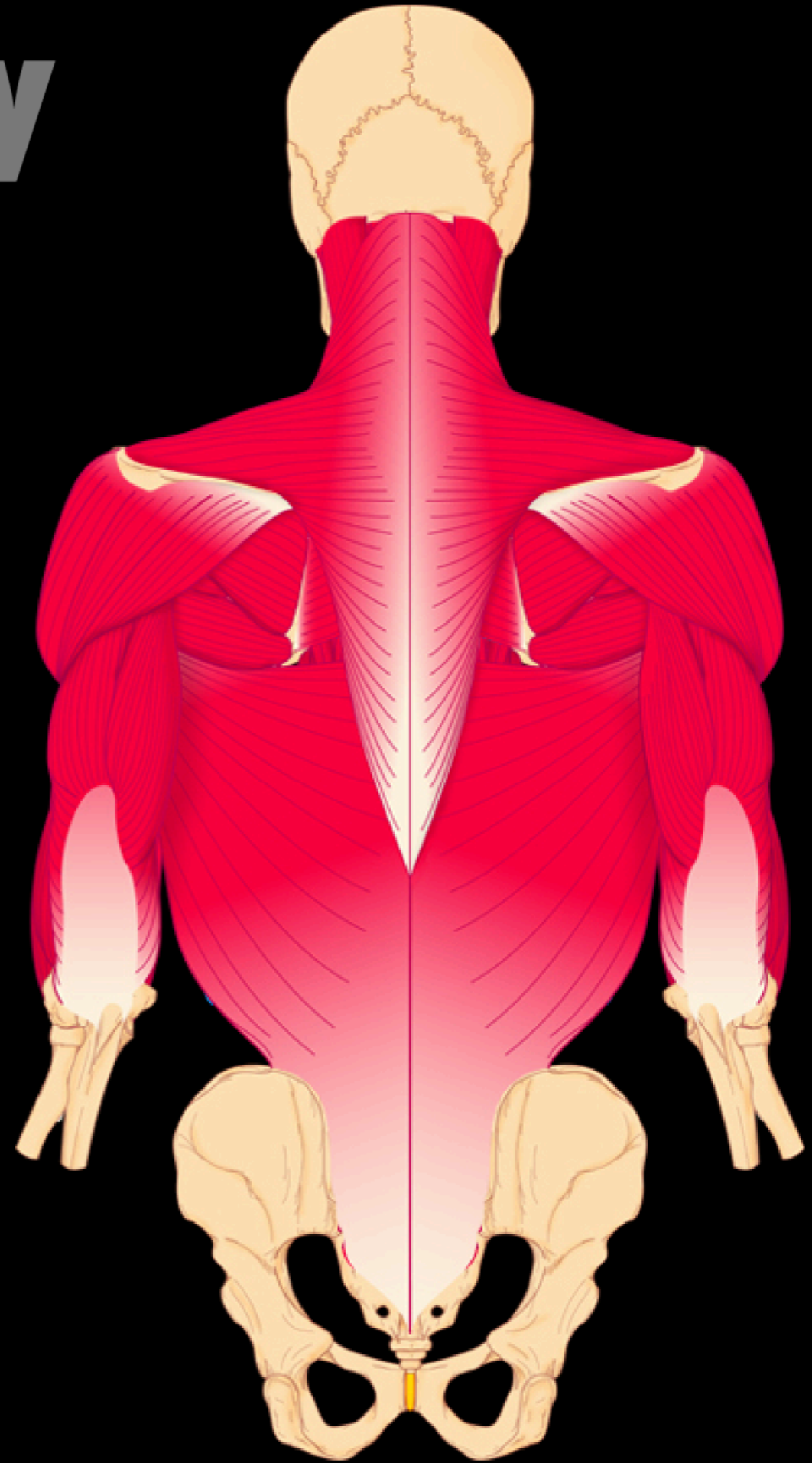
Extrinsic Back Muscles

What Are These Muscles?

Branchial limb muscles

Hypaxial body wall muscles

Hypaxial limb muscles

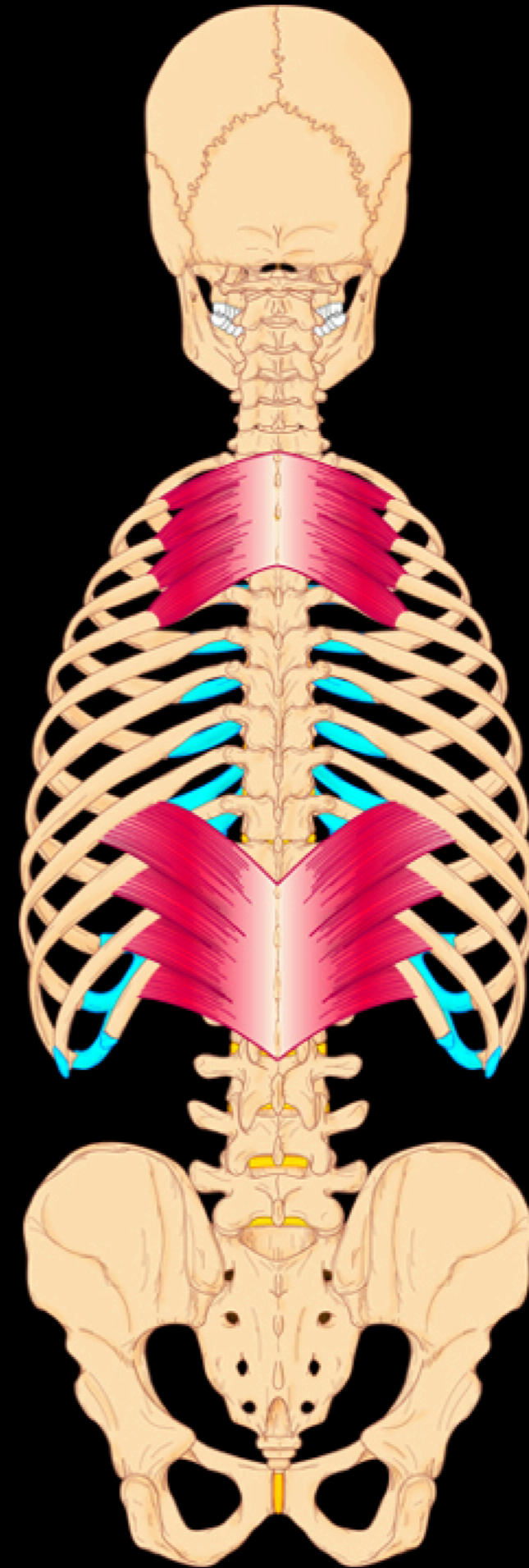


Back Anatomy

Extrinsic Back Muscles

Hypaxial Body Wall Muscles

Serratus posterior muscles

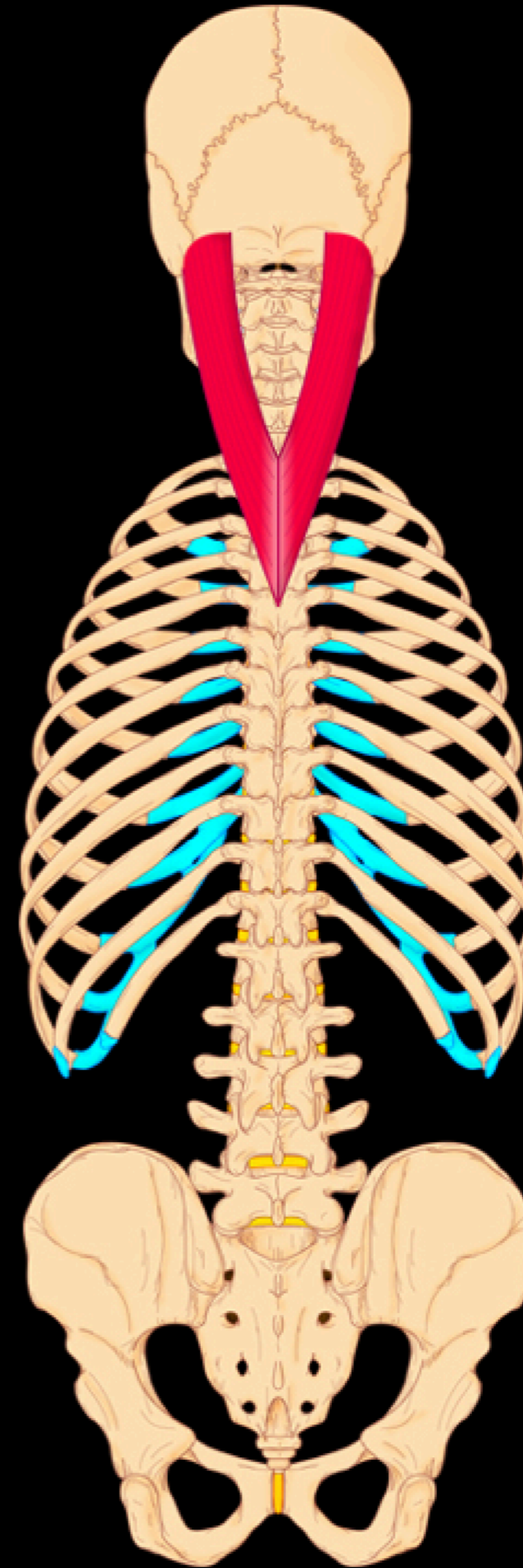


Back Anatomy

Intrinsic (Epaxial) Back Muscles

Superficial Spinotransversalis

Splenius capitis muscle

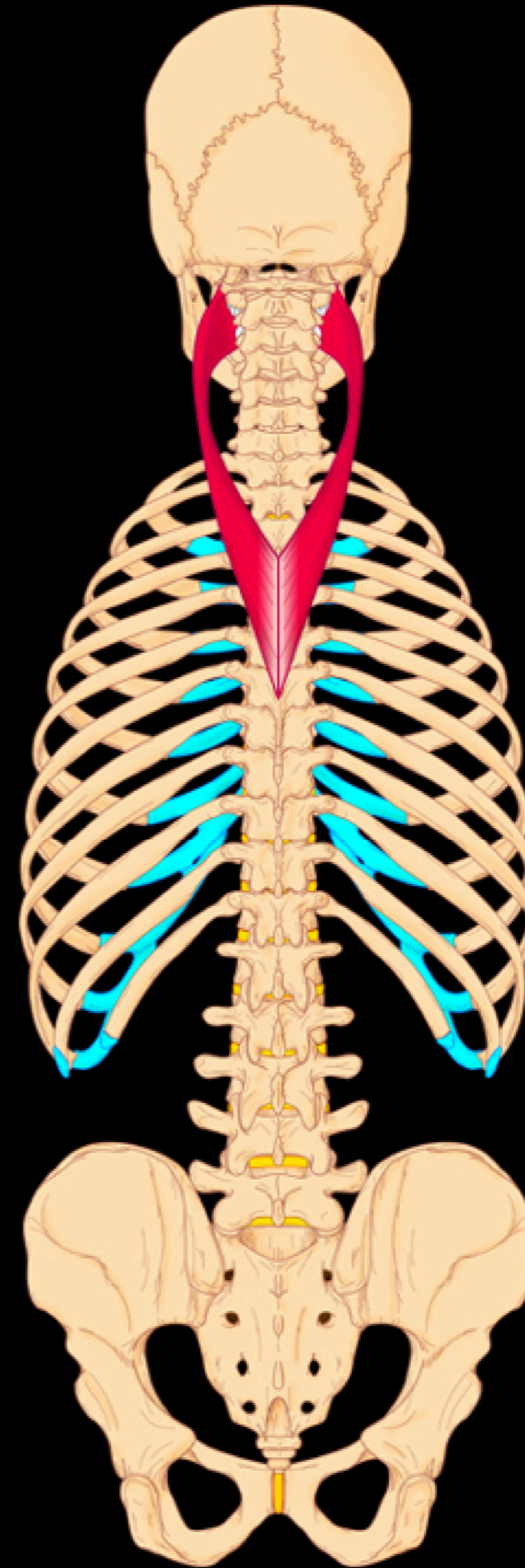


Back Anatomy

Intrinsic (Epaxial) Back Muscles

Superficial Spinotransversalis

Splenius cervicis muscle

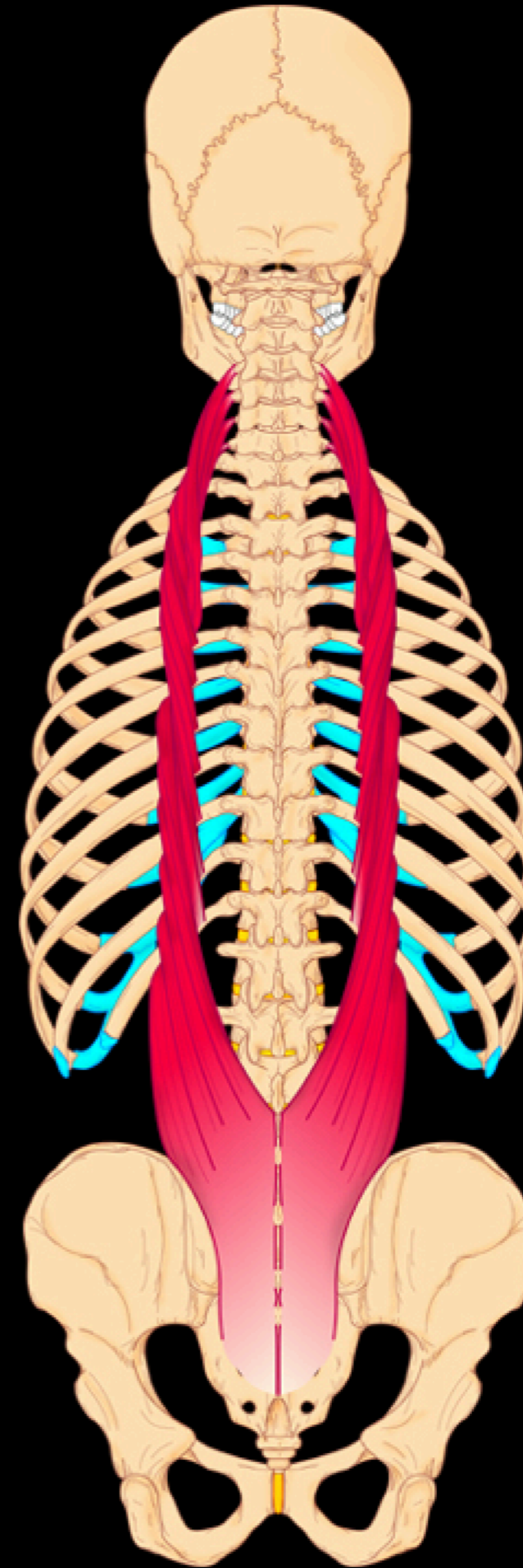


Back Anatomy

Intrinsic (Epaxial) Back Muscles

Superficial Erector Spinae

Iliocostalis muscle

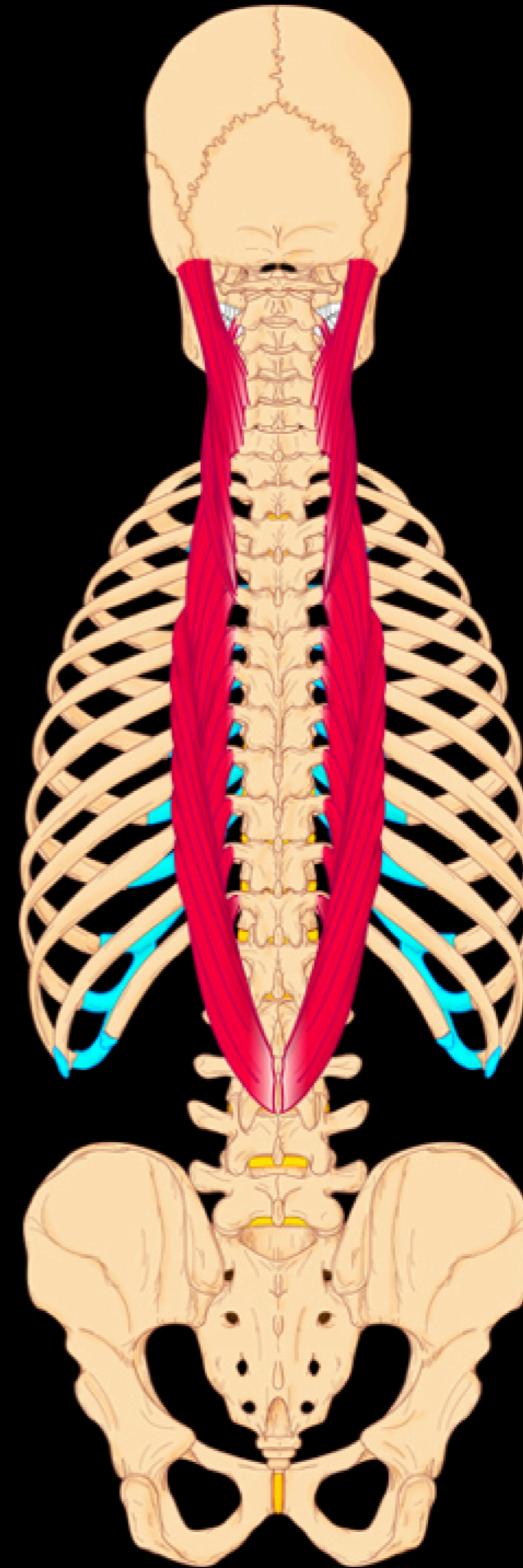


Back Anatomy

Intrinsic (Epaxial) Back Muscles

Superficial Erector Spinae

Longissimus muscle

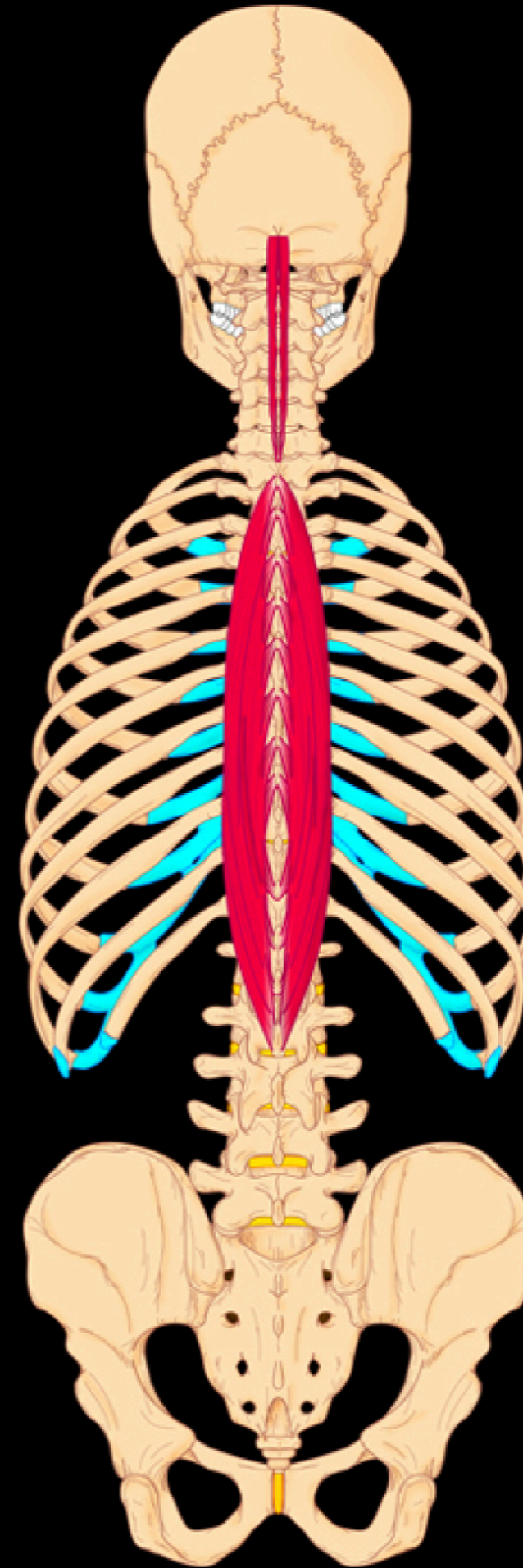


Back Anatomy

Intrinsic (Epaxial) Back Muscles

Superficial Erector Spinae

Spinalis muscle

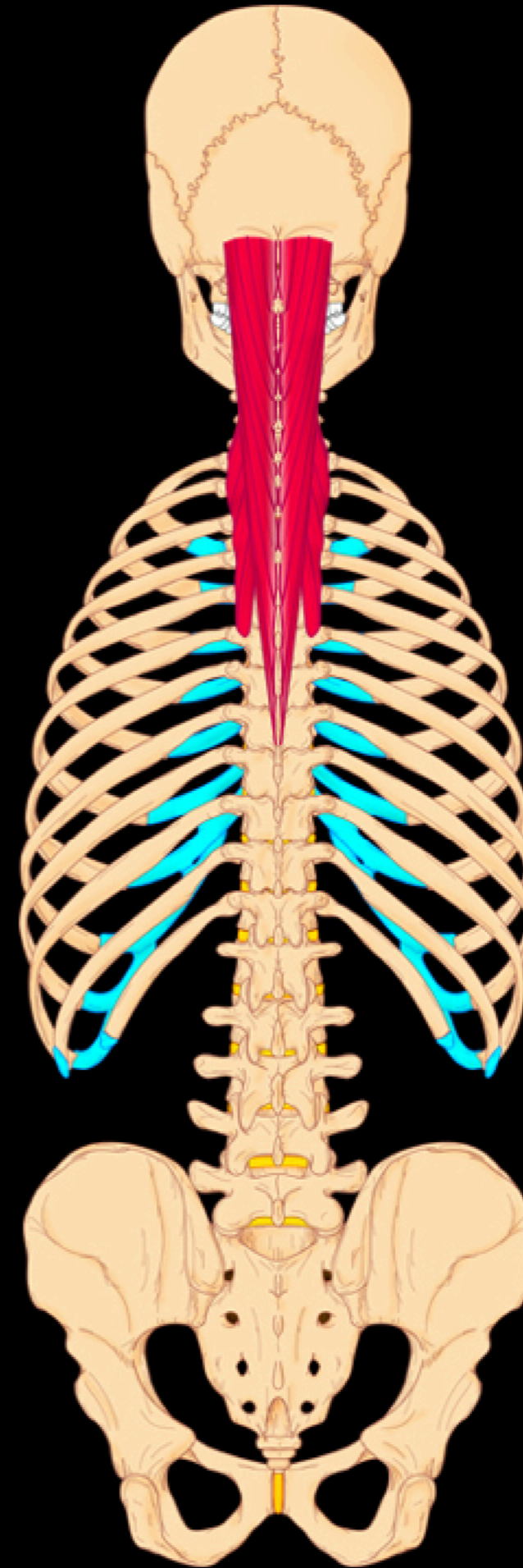


Back Anatomy

Intrinsic (Epaxial) Back Muscles

Deep Transversospinalis

Semispinalis muscle

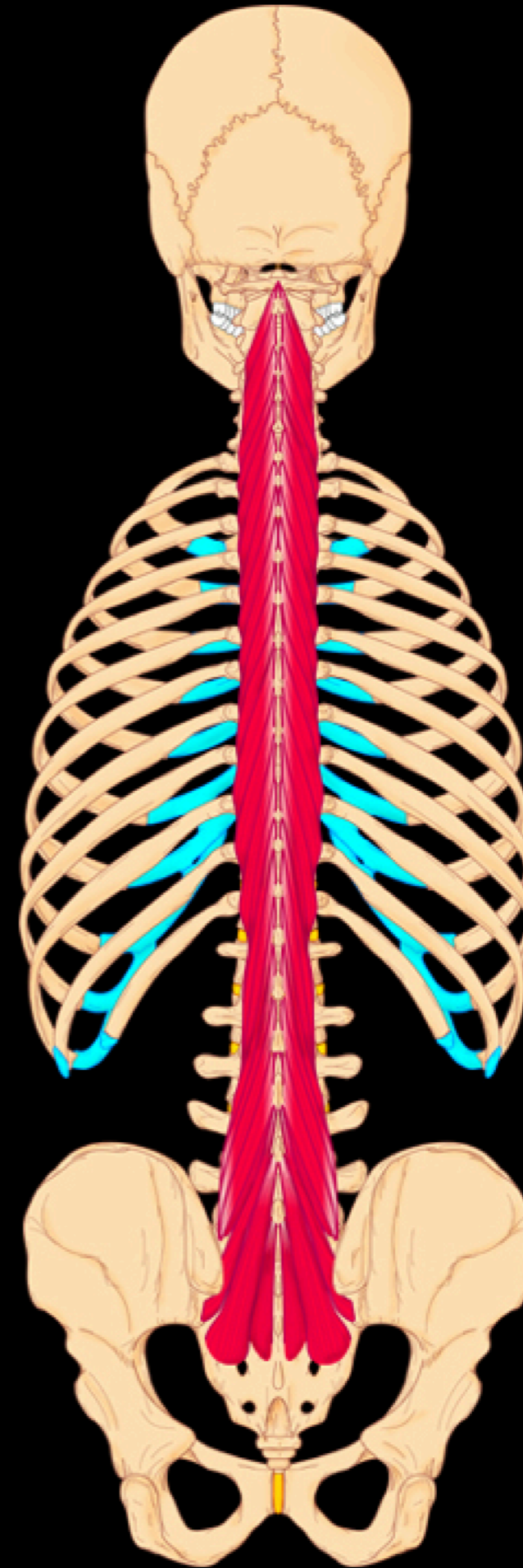


Back Anatomy

Intrinsic (Epaxial) Back Muscles

Deep Transversospinalis

Multifidus muscle

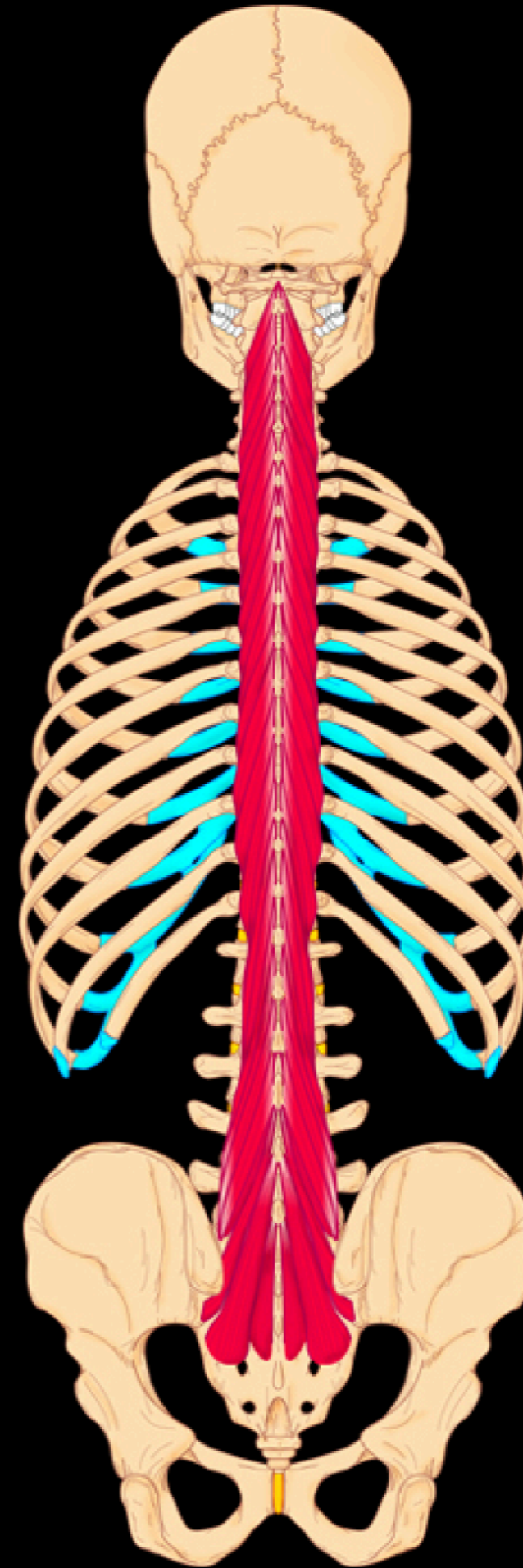


Back Anatomy

Intrinsic (Epaxial) Back Muscles

Deep Transversospinalis

Multifidus muscle



Back Anatomy

Epaxial Muscle Innervation

Posterior or Dorsal Ramus

