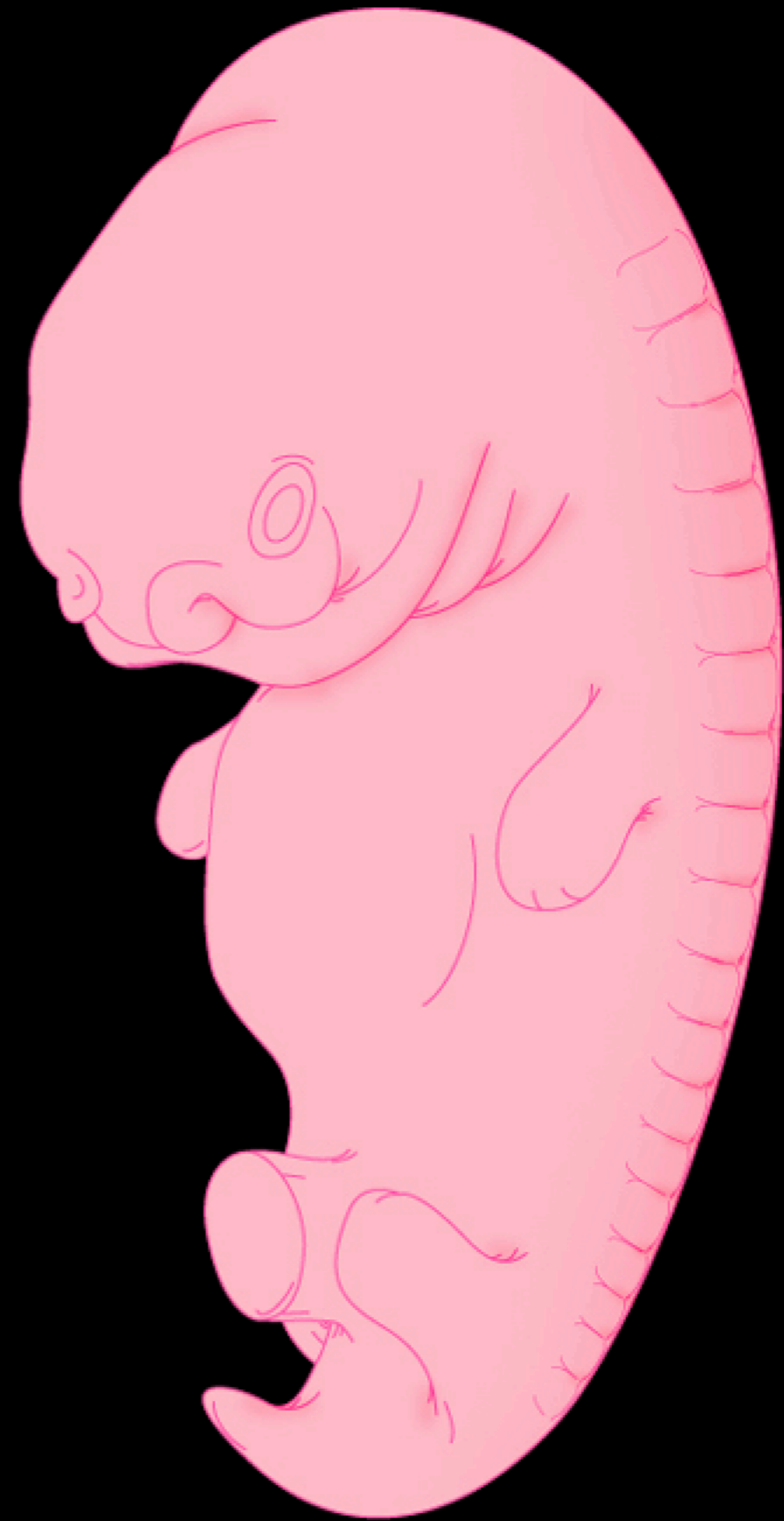


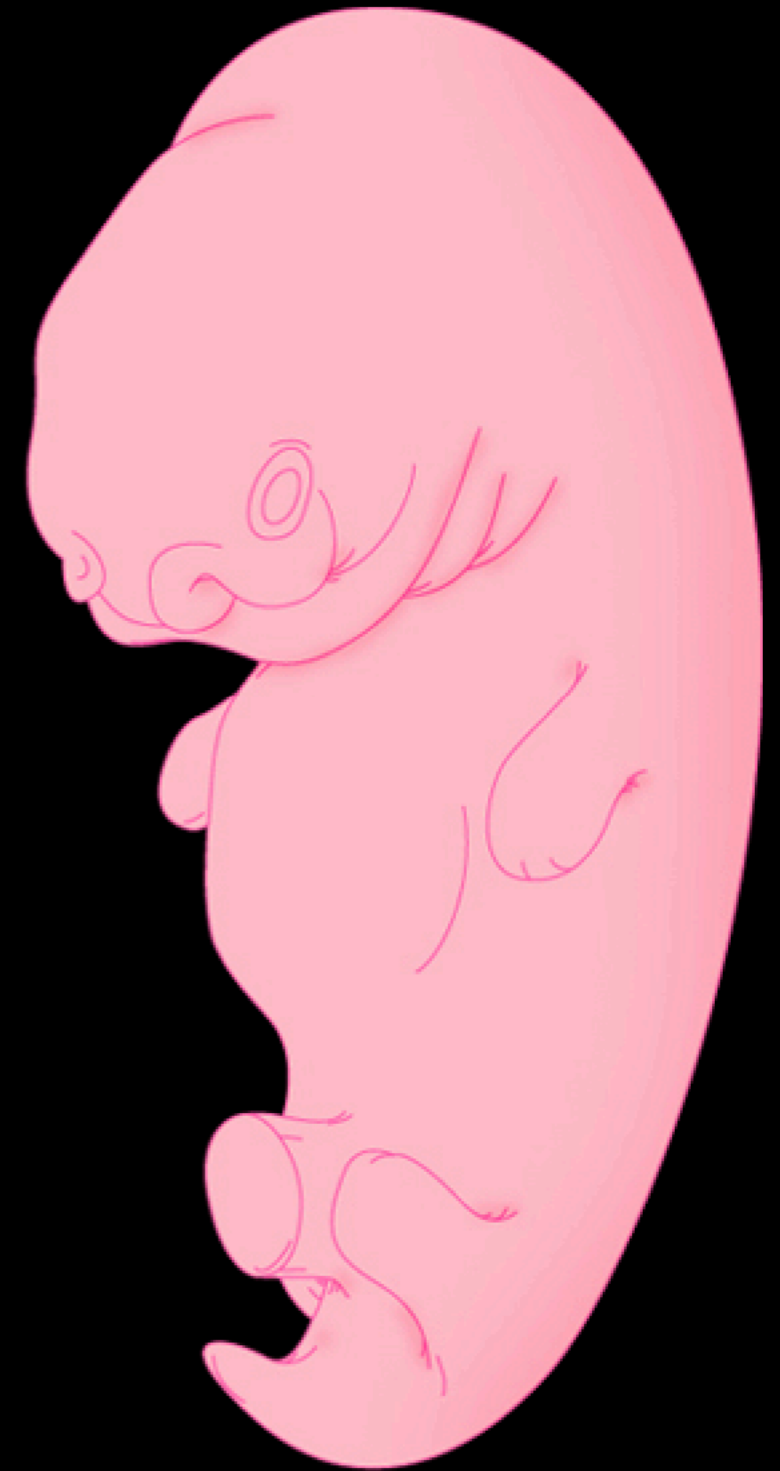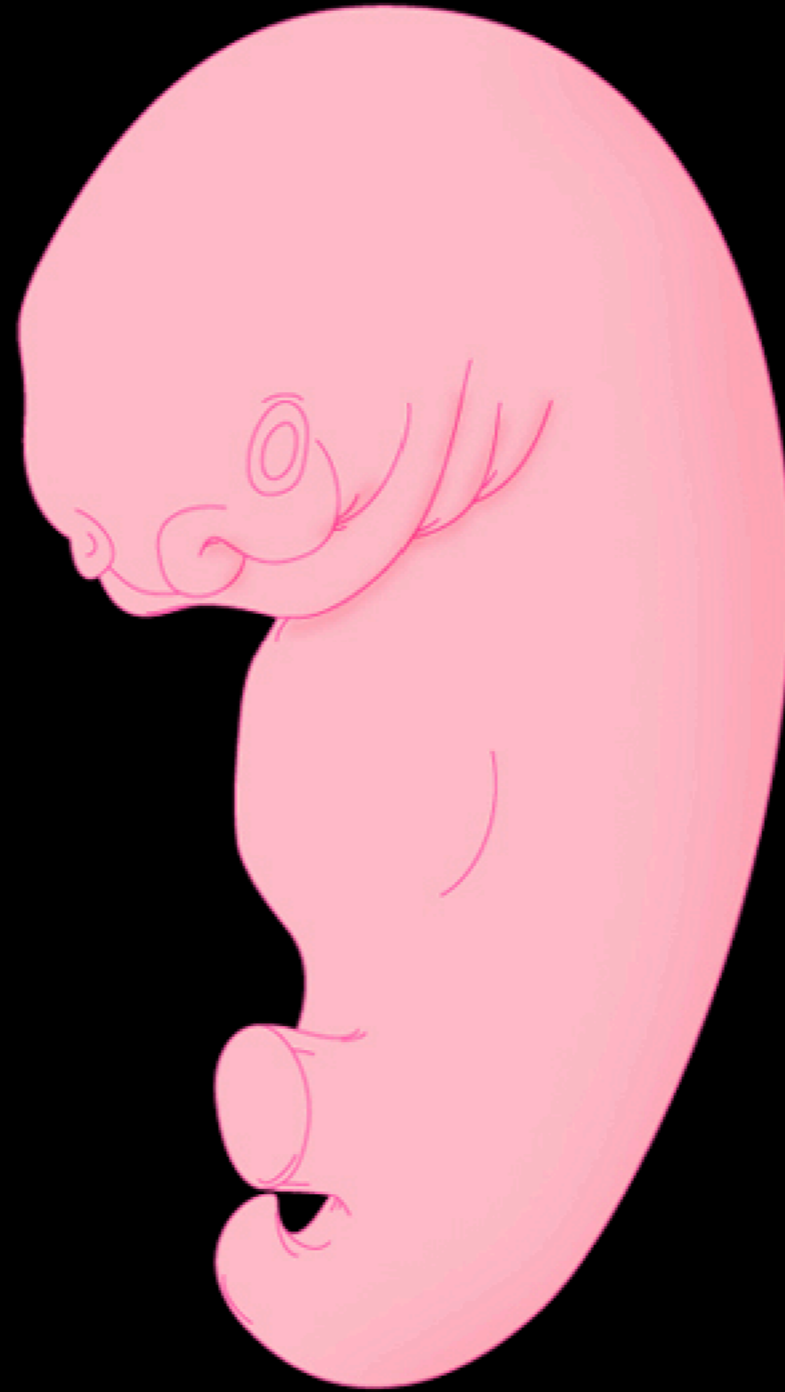Limb Design



Limb Design

Origin of Vertebrate Limbs

Hypaxial Body Wall and Limb Bud



Limb Design

Development of the Limb

Bones

Lateral mesoderm condensation

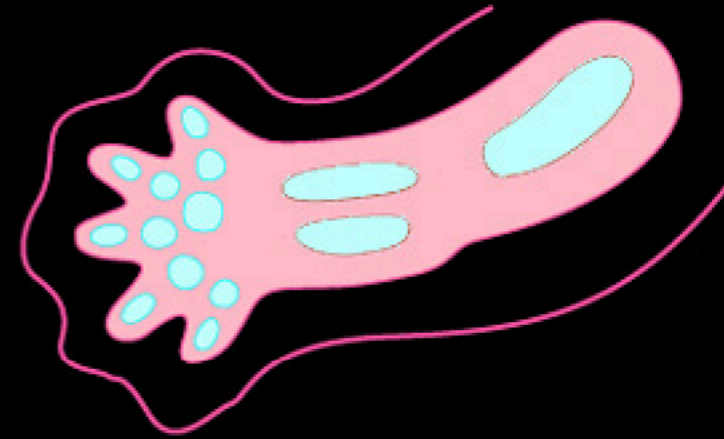


Limb Design

Development of the Limb

Bones

Cartilage formation

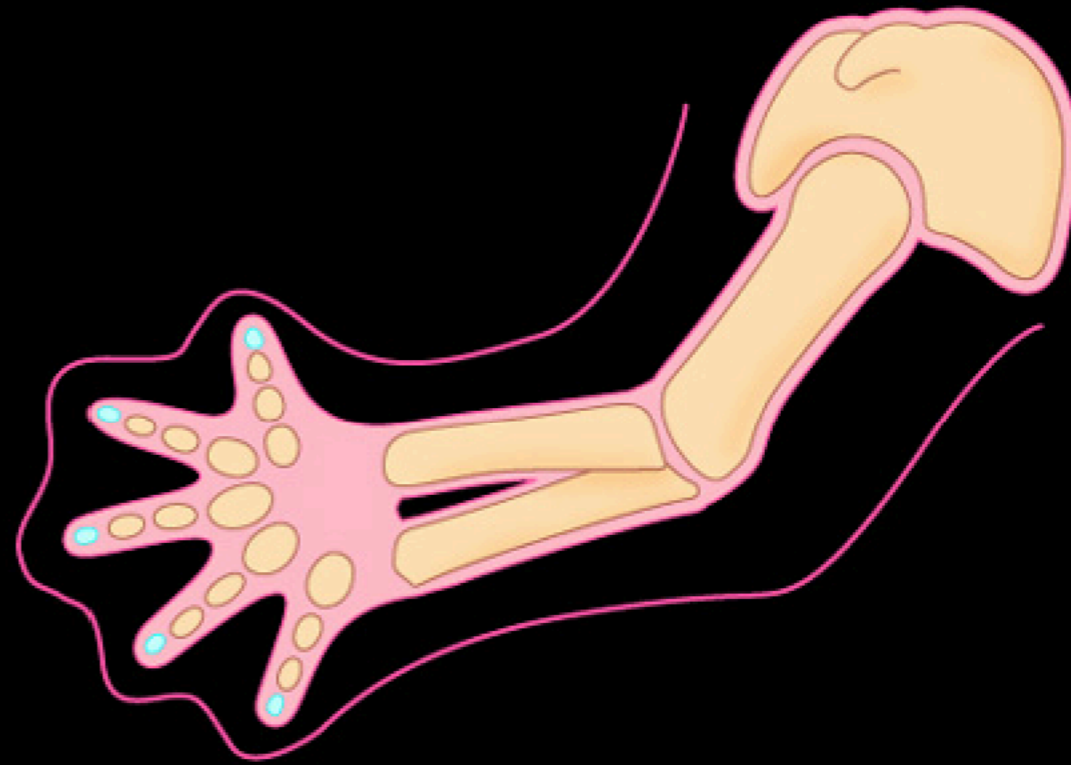

Limb Design

Development of the Limb

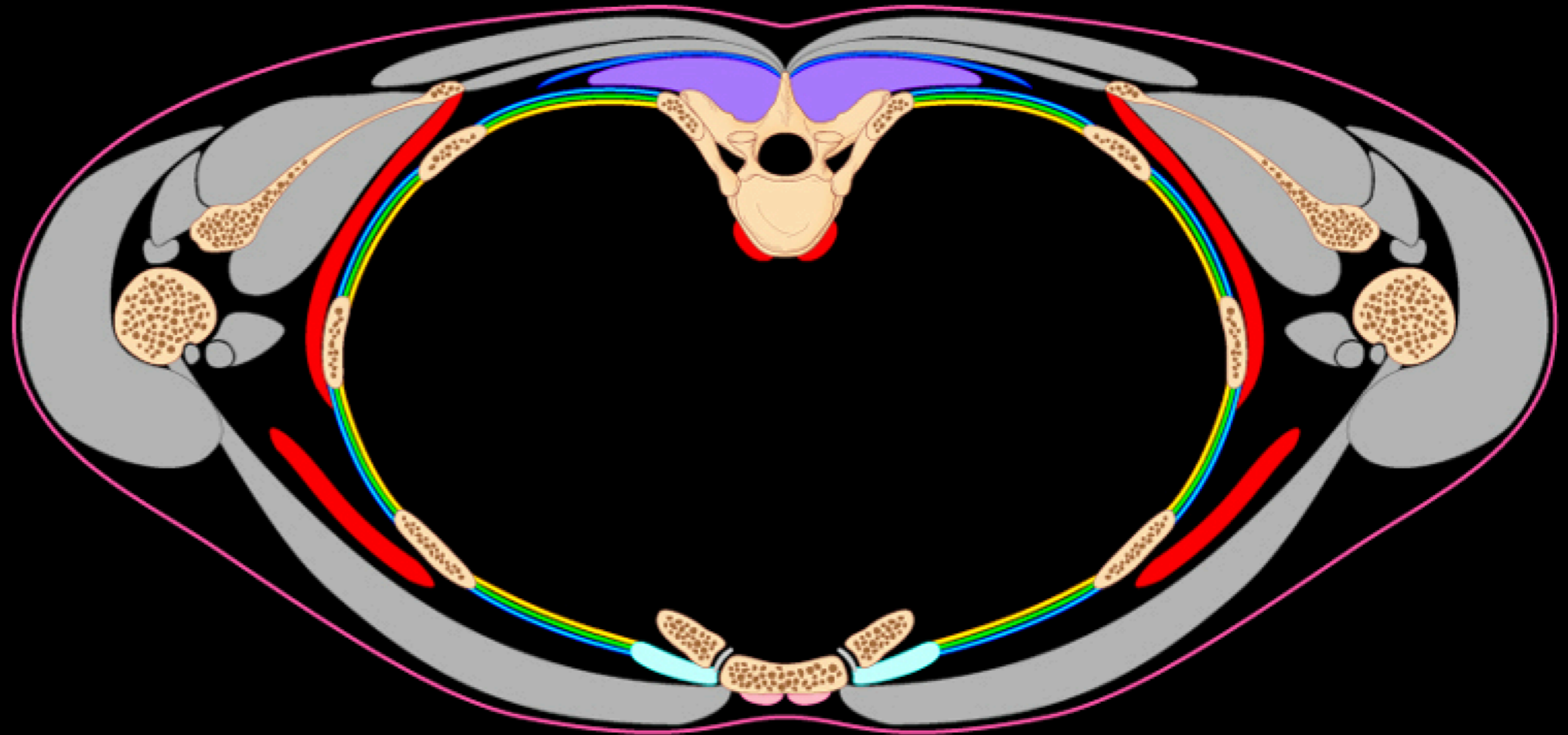
Bones

Bone formation



Muscles

Annexation of outermost body wall muscles

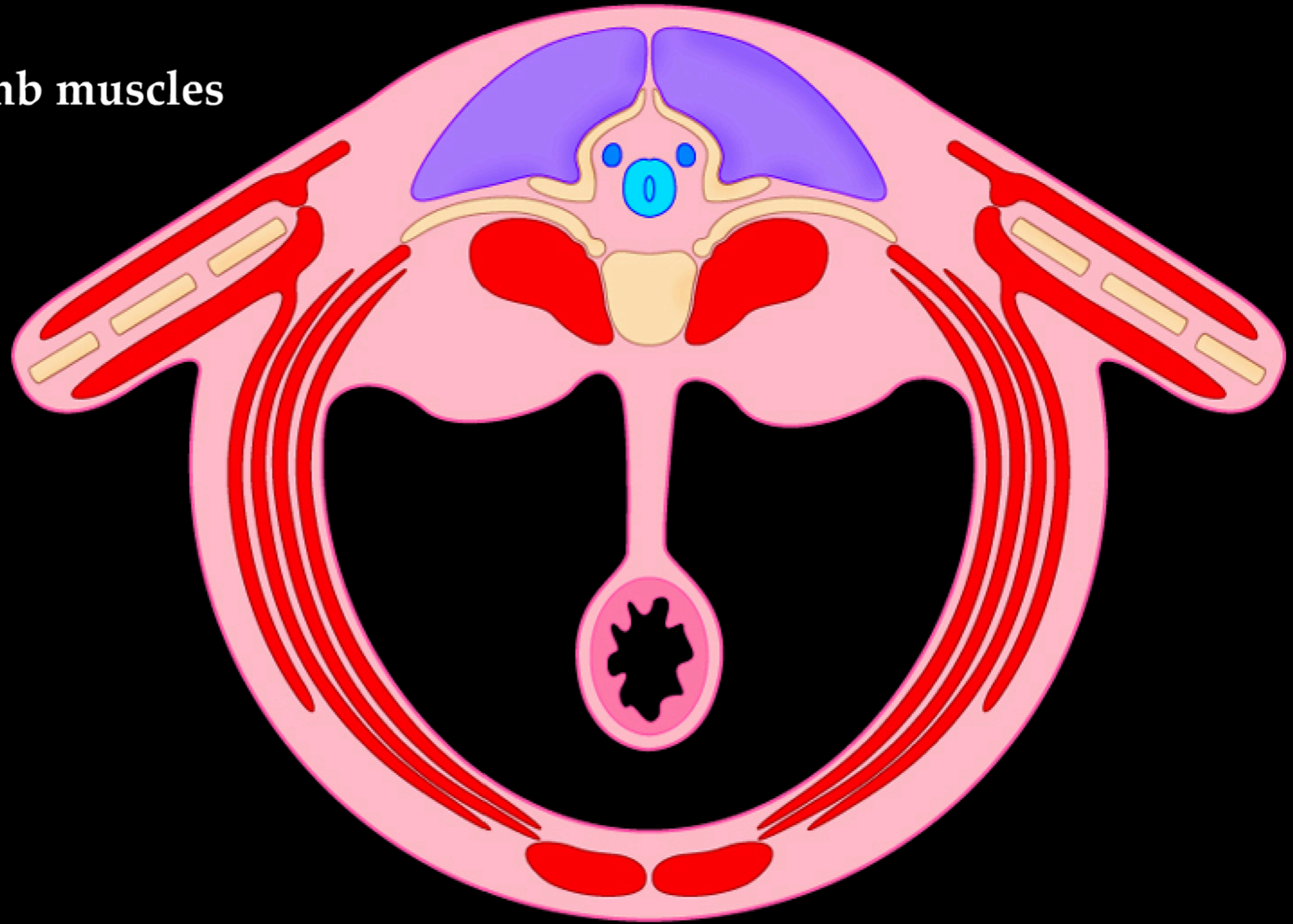


Limb Design

Development of the Limb

Muscles

Proximal limb muscles

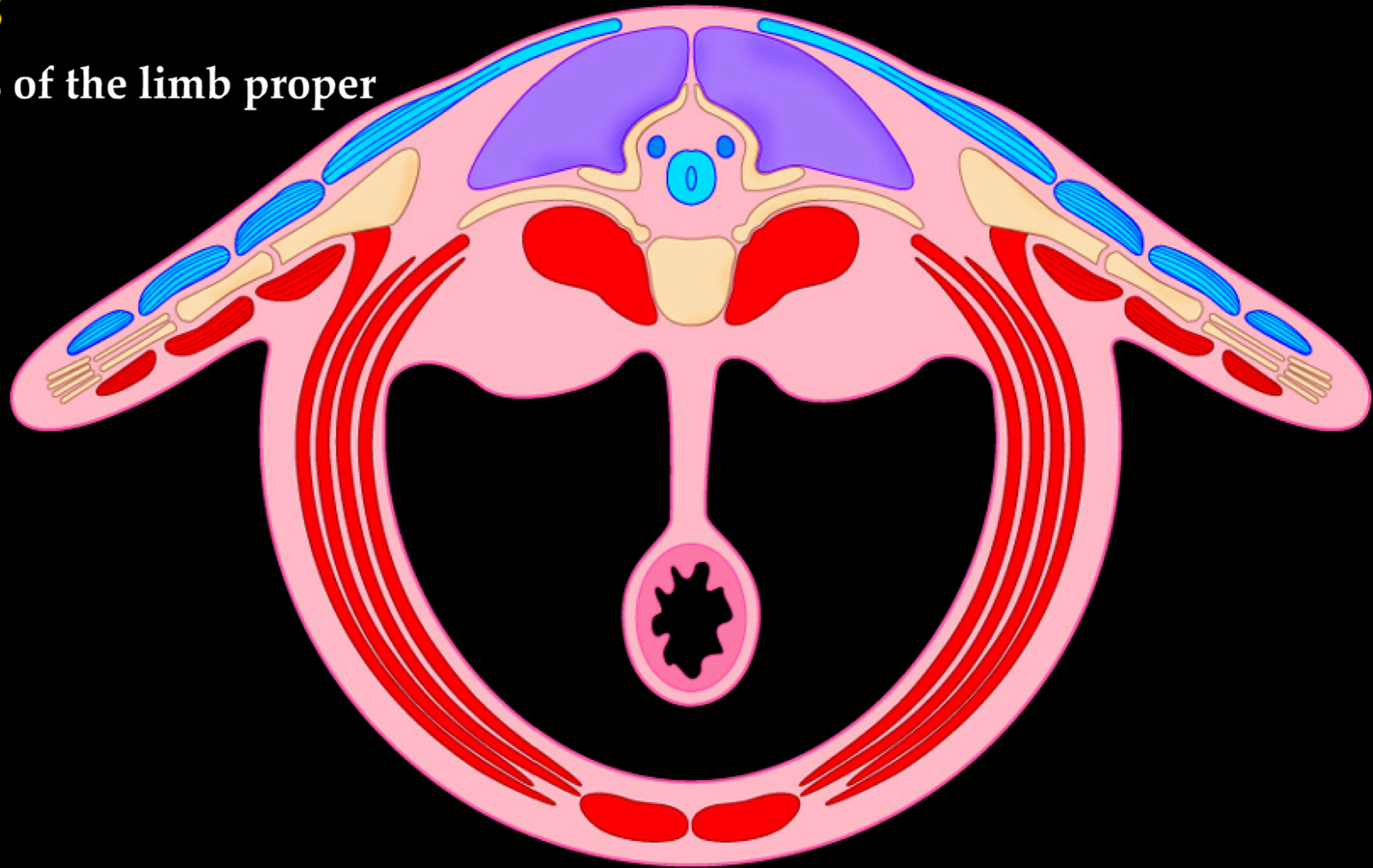


Limb Design

Development of the Limb

Muscles

Muscles of the limb proper

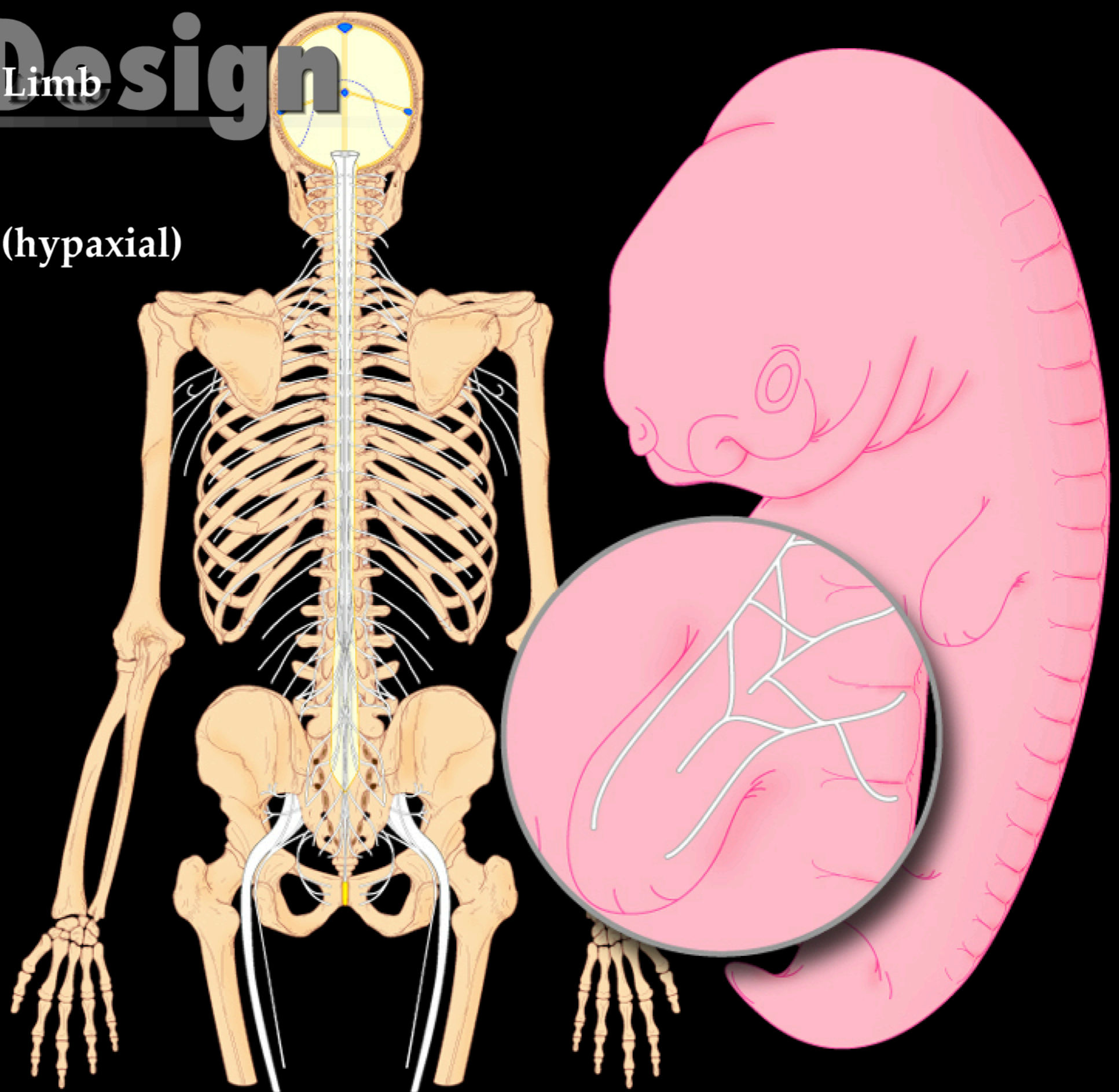


Limb Design

Development of the Limb

Nerves

Ventral ramus (hypaxial)

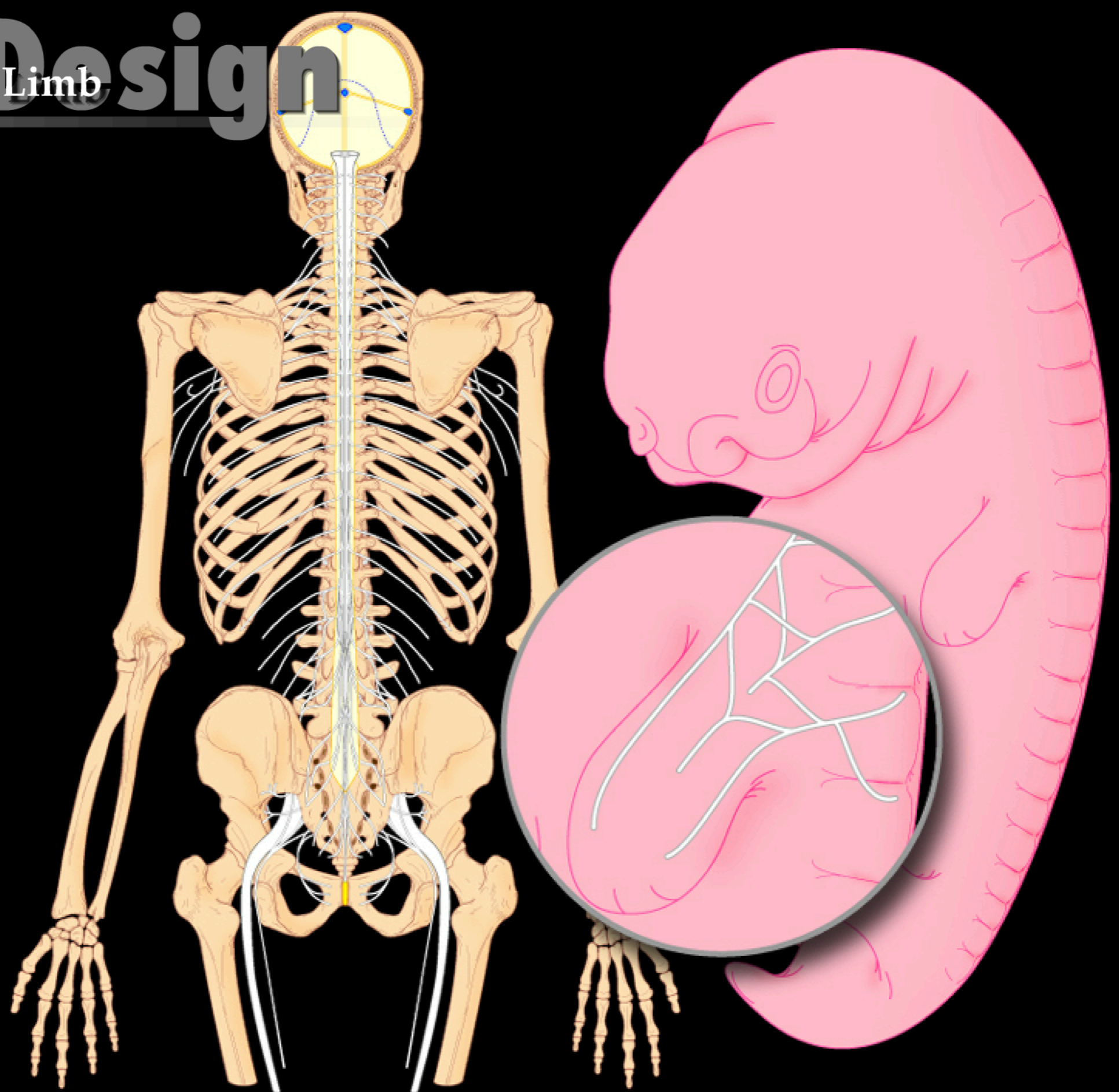


Limb Design

Development of the Limb

Nerves

Plexus concept

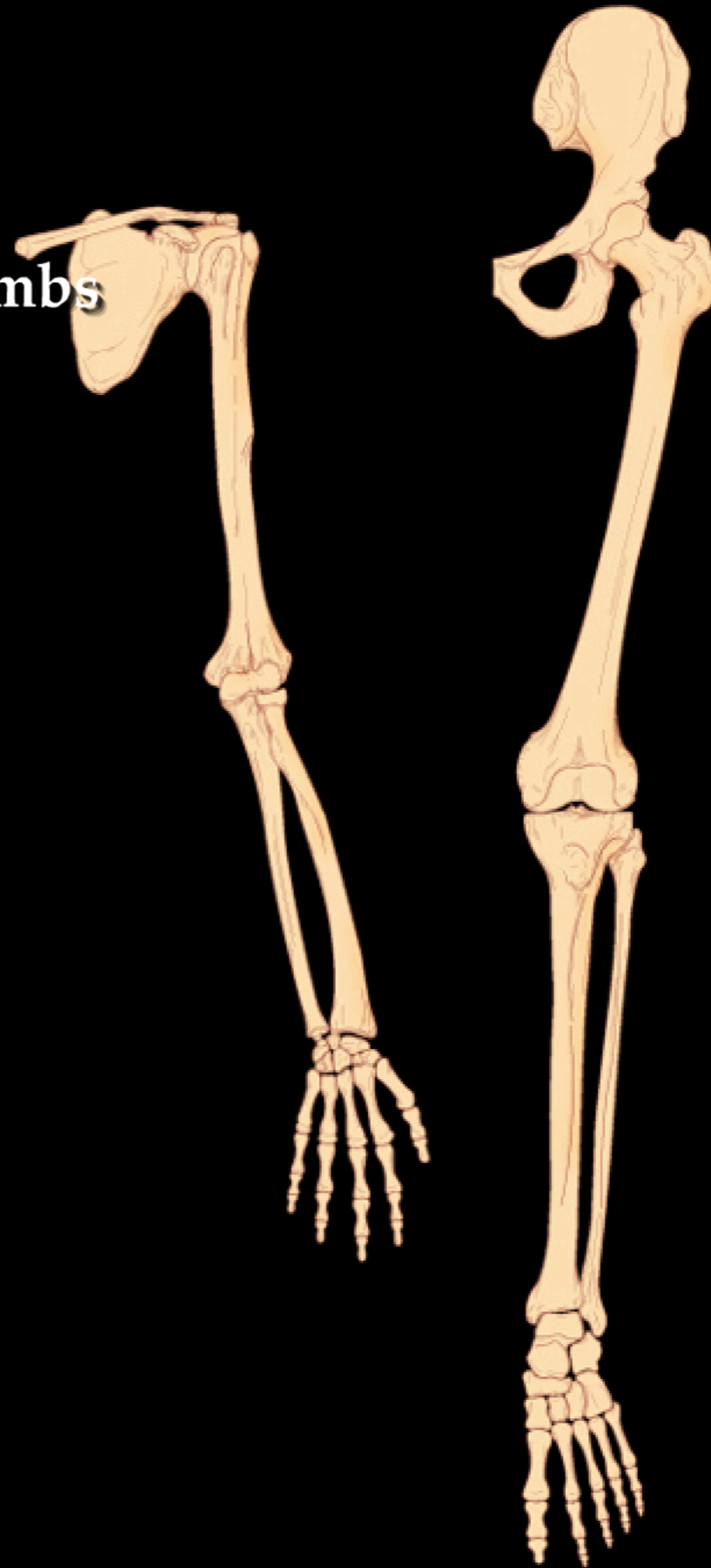


Limb Design

Limb Bones

Bones

Compare the similarities between the limbs

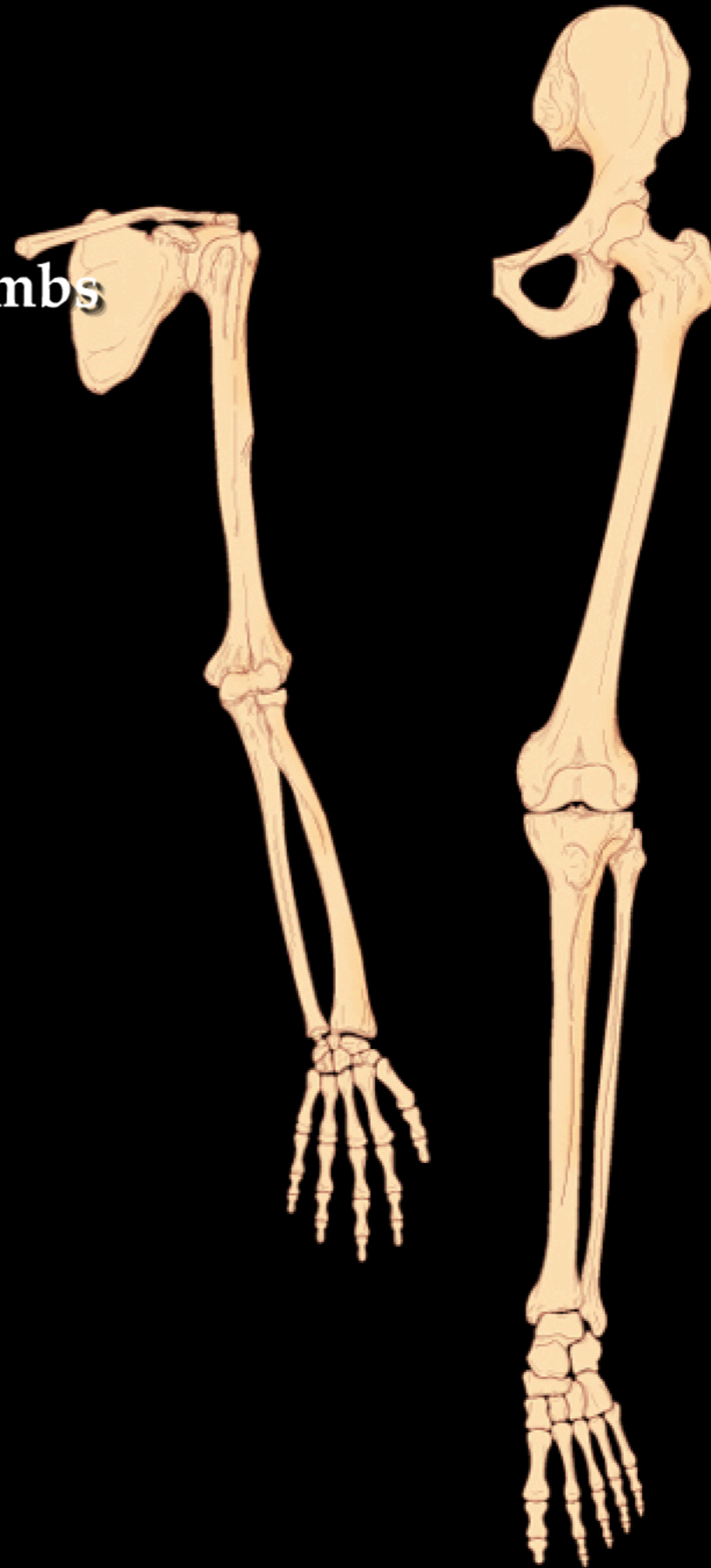


Limb Design

Limb Bones

Joints

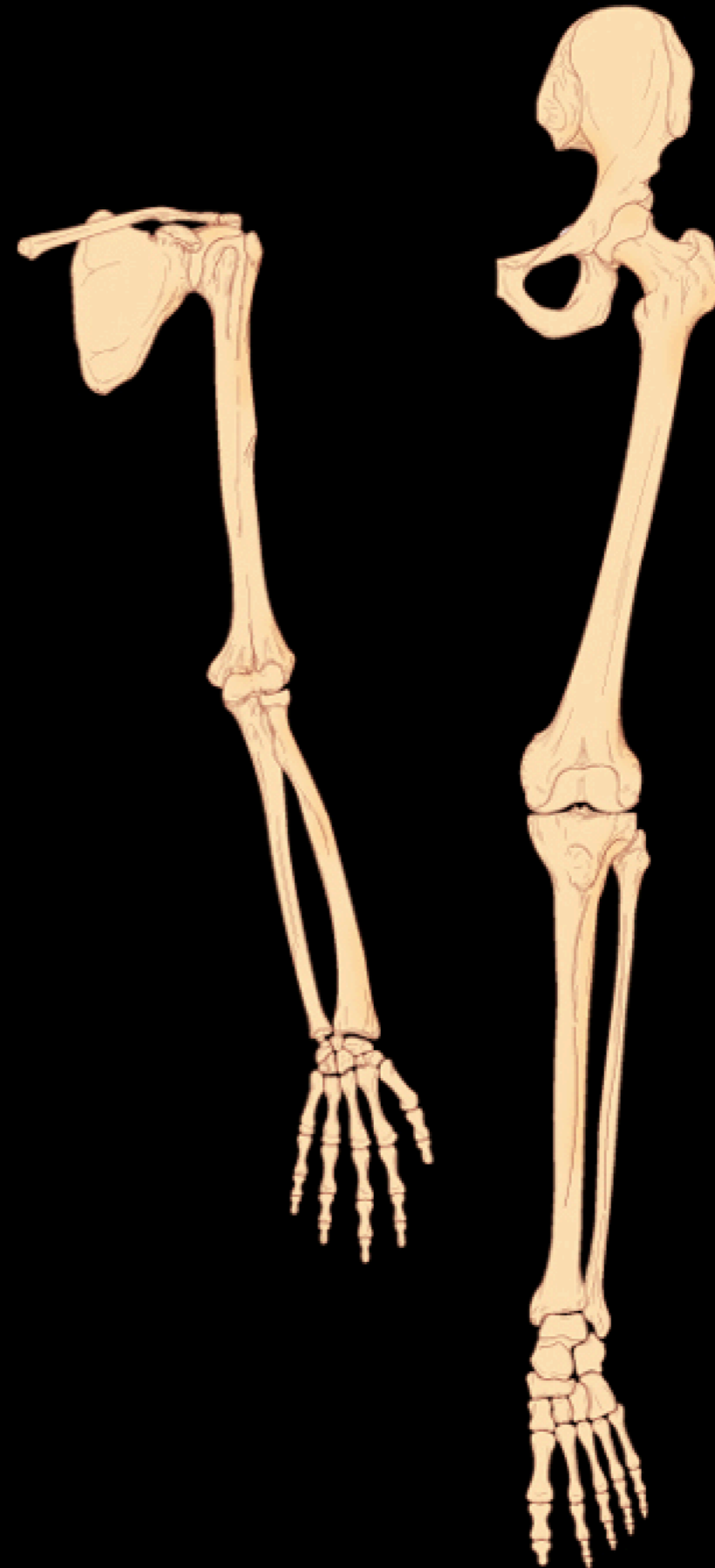
Compare the similarities between the limbs



Limb Bones

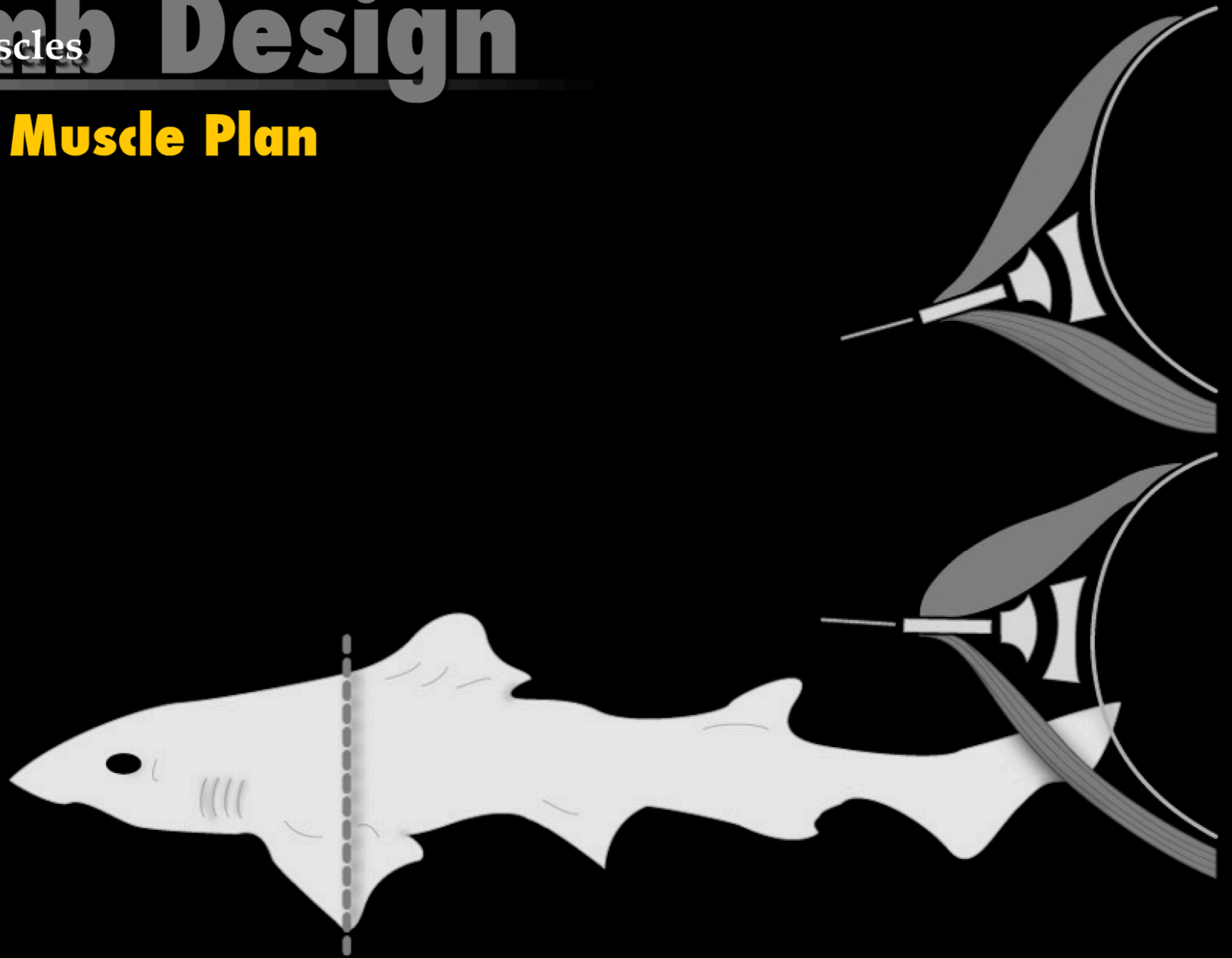
Limb Design

Why the Differences?



Limb Design

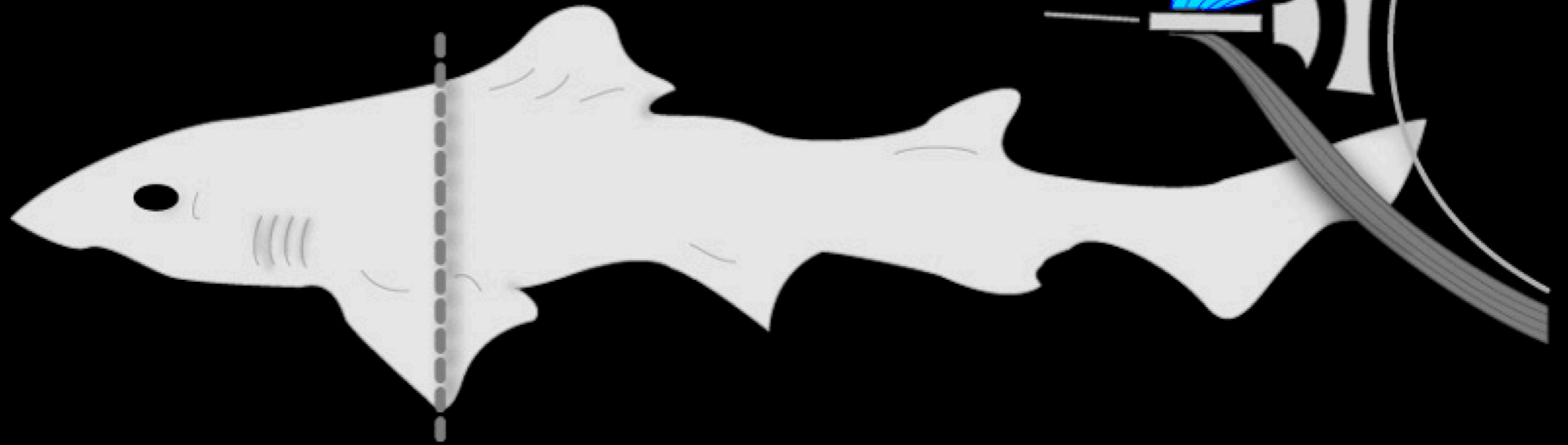
Basic Muscle Plan



Limb Design

Primitive Vertebrate Limb

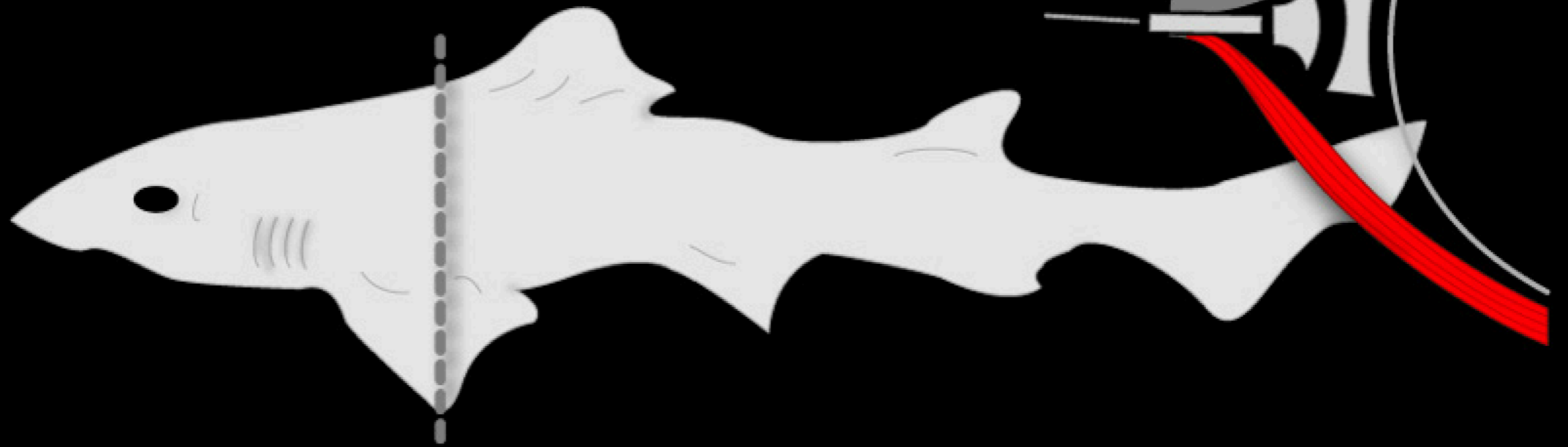
Elevator (dorsal) muscles



Limb Design

Primitive Vertebrate Limb

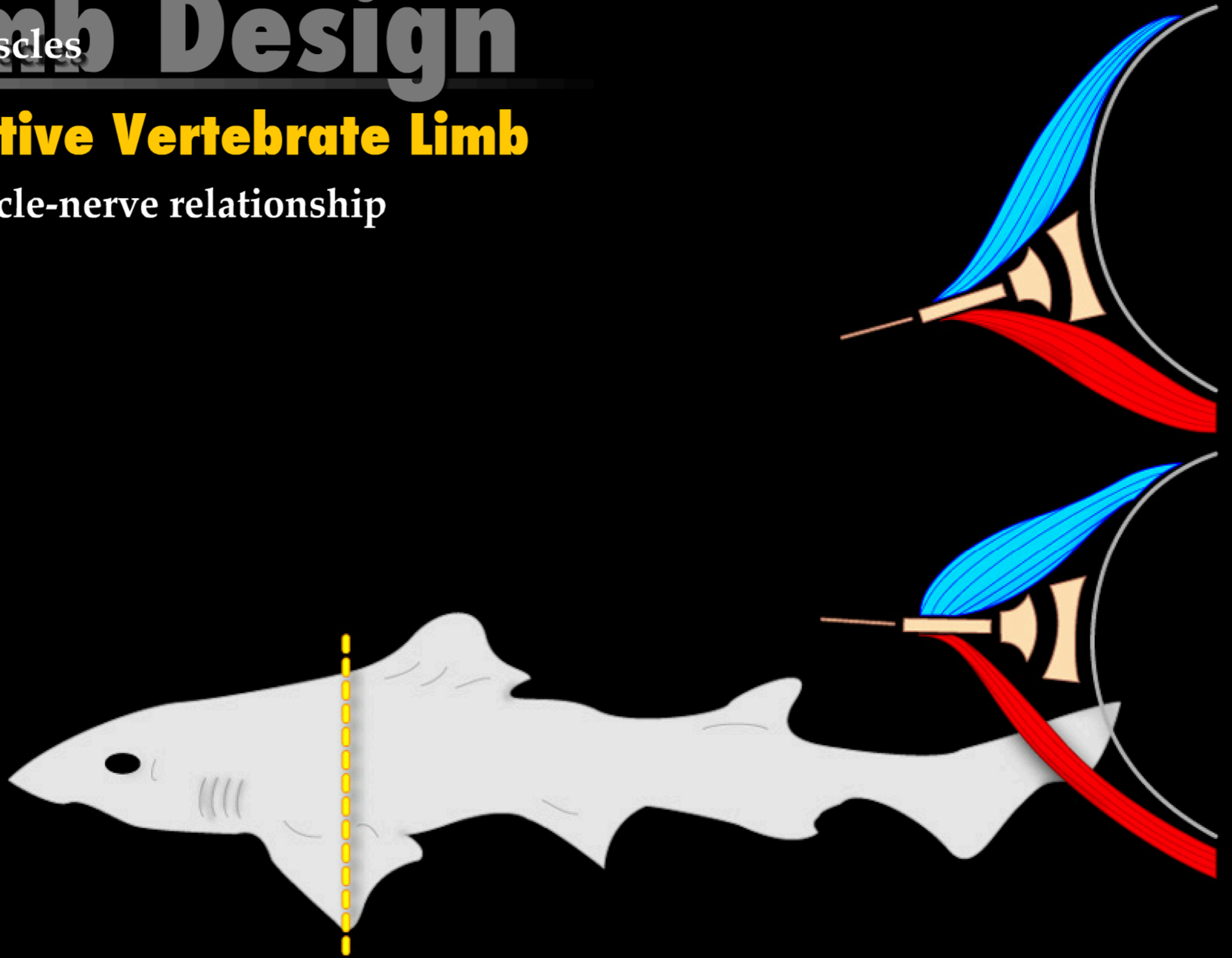
Depressor (ventral) muscles



Limb Design

Primitive Vertebrate Limb

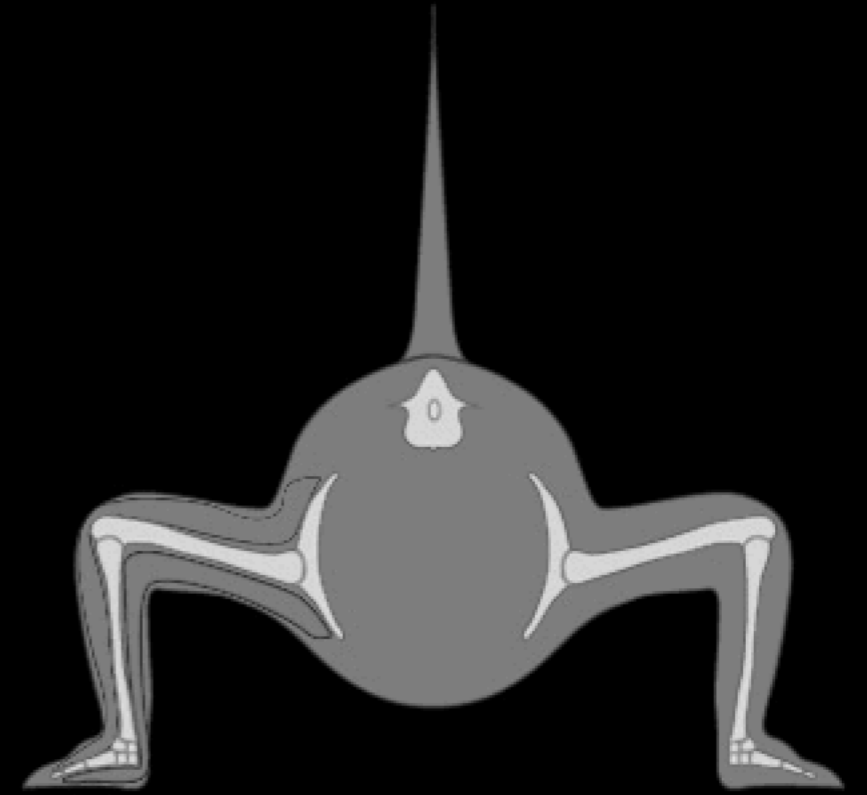

Muscle-nerve relationship



Limb Design

Limb Muscles

Premammalian Limb

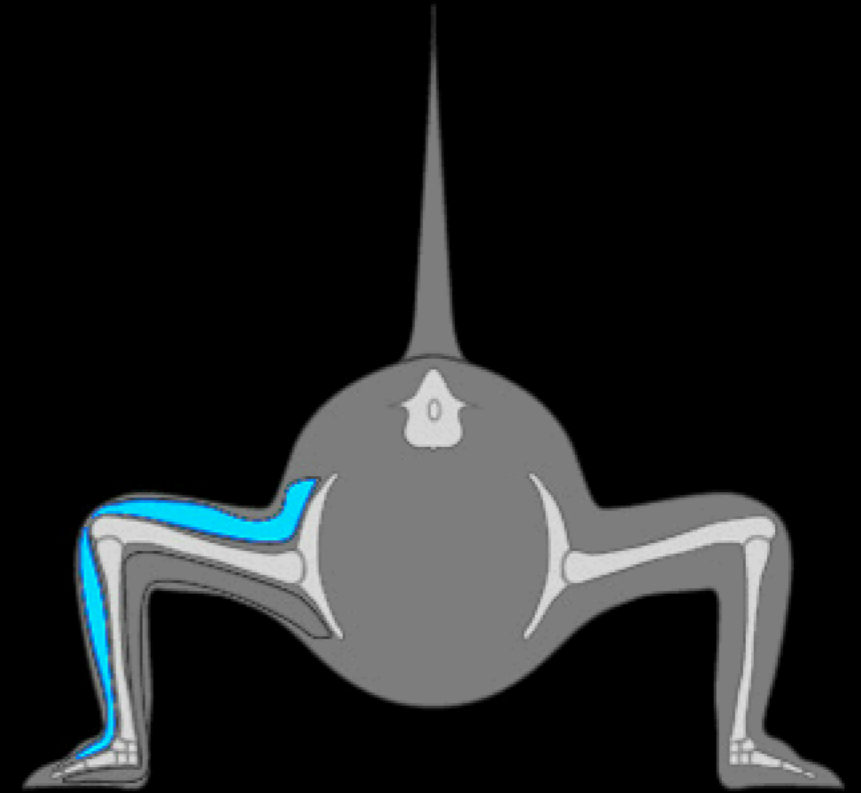



Limb Design

Limb Muscles

Premammalian Limb

Elevator (dorsal) muscles




Limb Design

Limb Muscles

Premammalian Limb

Depressor (ventral) muscles




Limb Design

Limb Muscles

Premammalian Limb

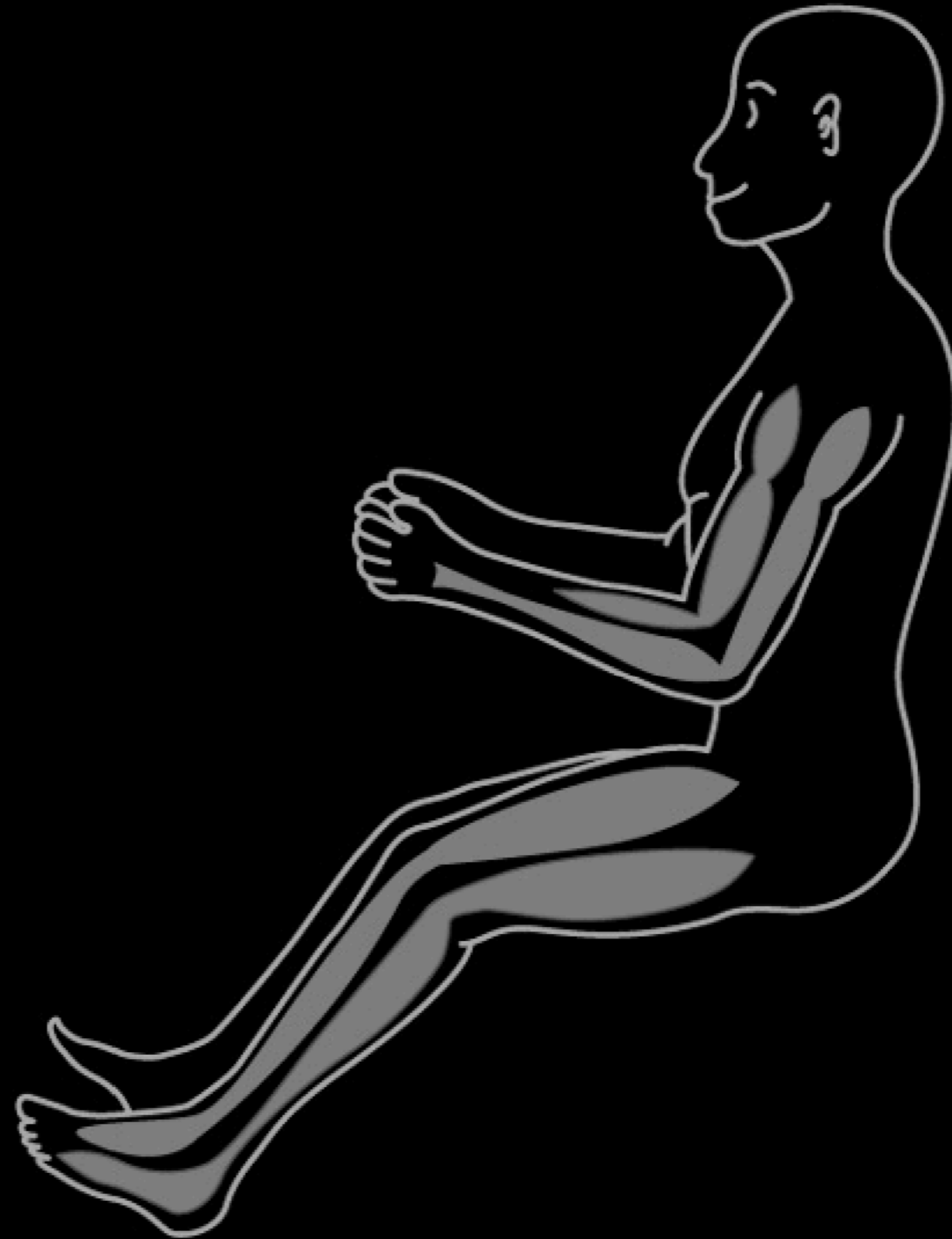
Muscle-nerve relationship



Limb Design

Limb Muscles

Mammalian Limb

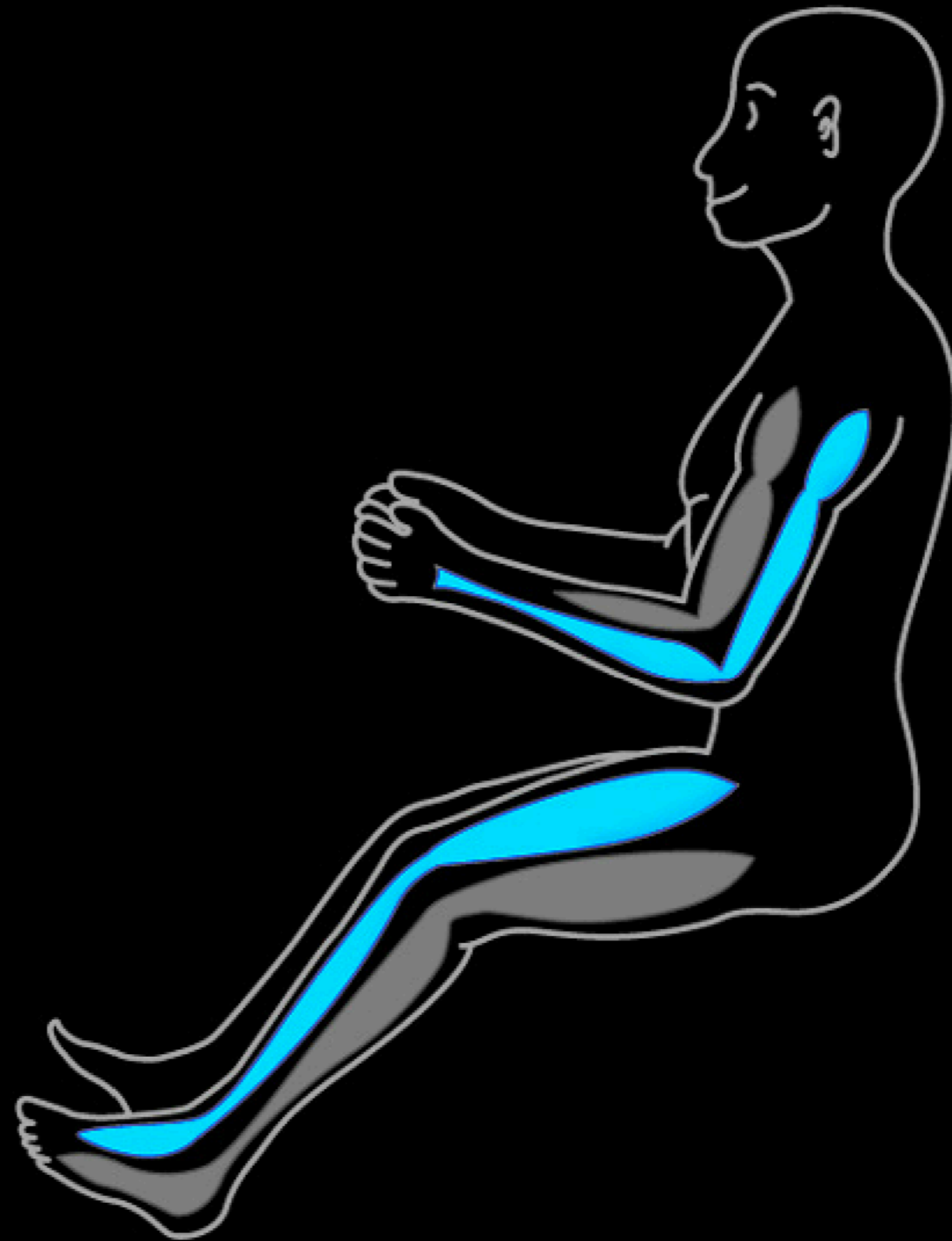


Limb Design

Limb Muscles

Mammalian Limb

Elevator (dorsal) muscles

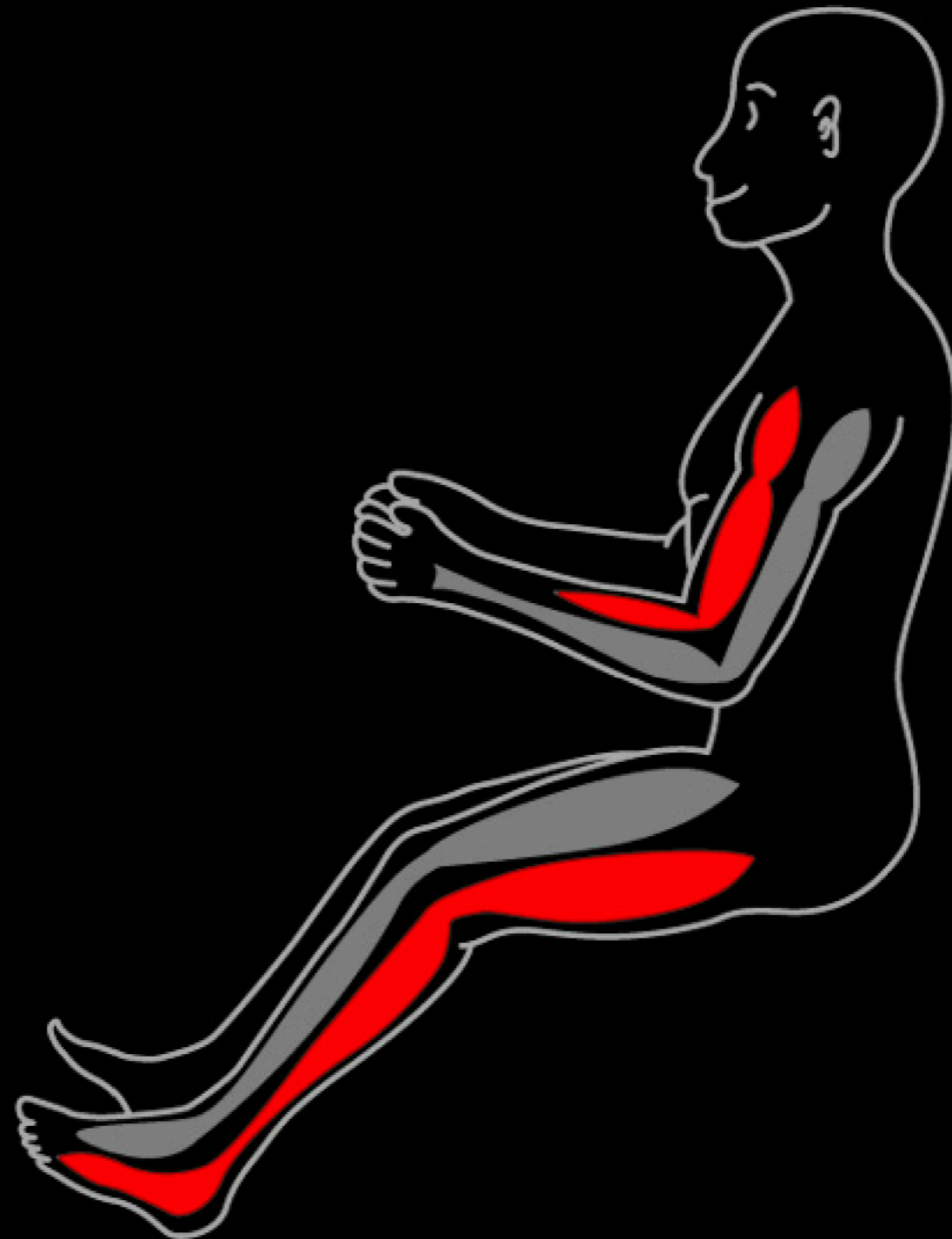

Limb Muscles Design

Limb Muscles

Mammalian Limb

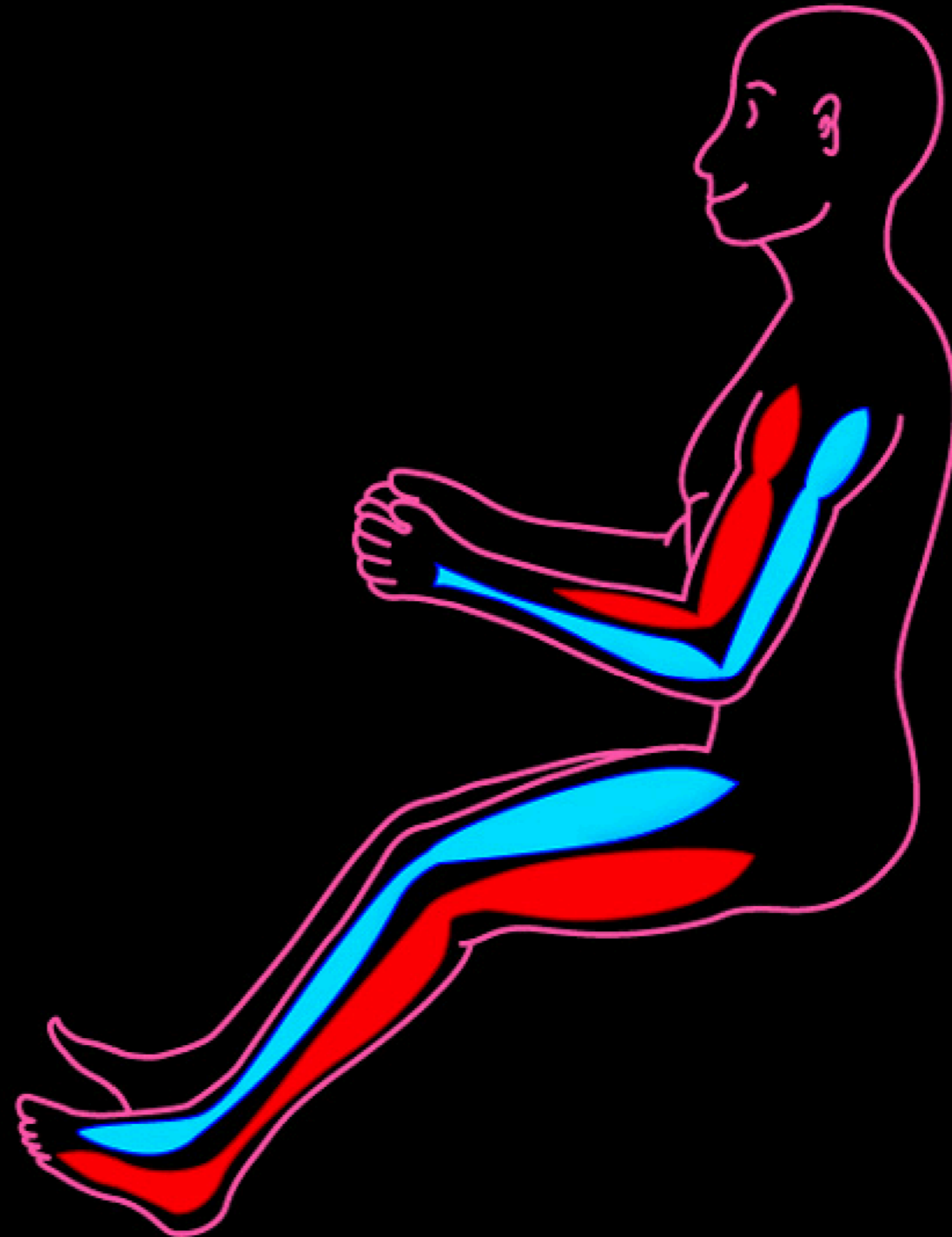
Depressor (ventral) muscles



Limb Design

Mammalian Limb

Muscle-nerve relationship




Limb Design

Mammalian Limb Rotation

Embryonic Limb

Muscle-nerve relationship

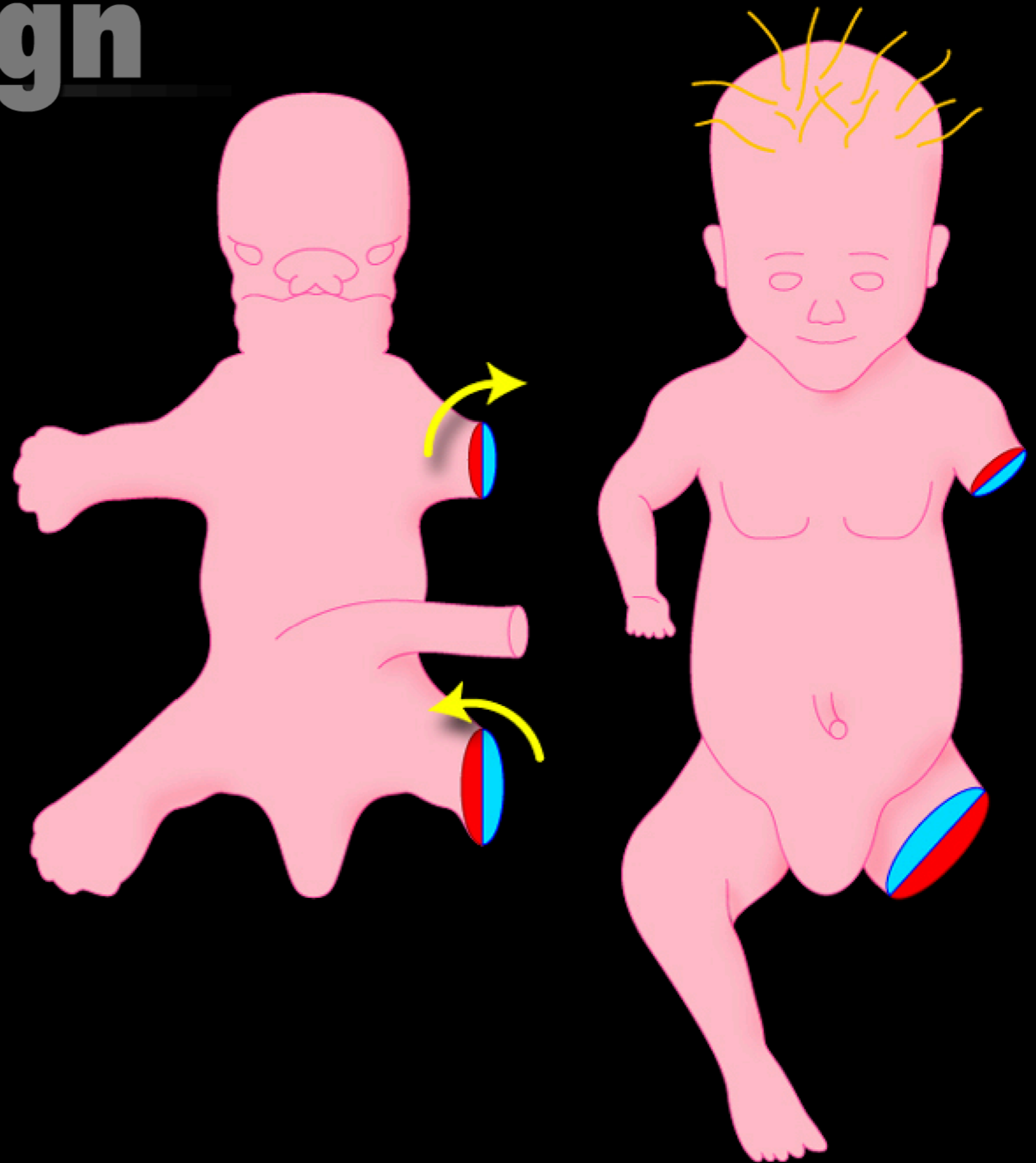


Limb Design


Mammalian Limb Rotation

Postnatal Limb

Muscle-nerve relationship



Mammalian Limb Rotation

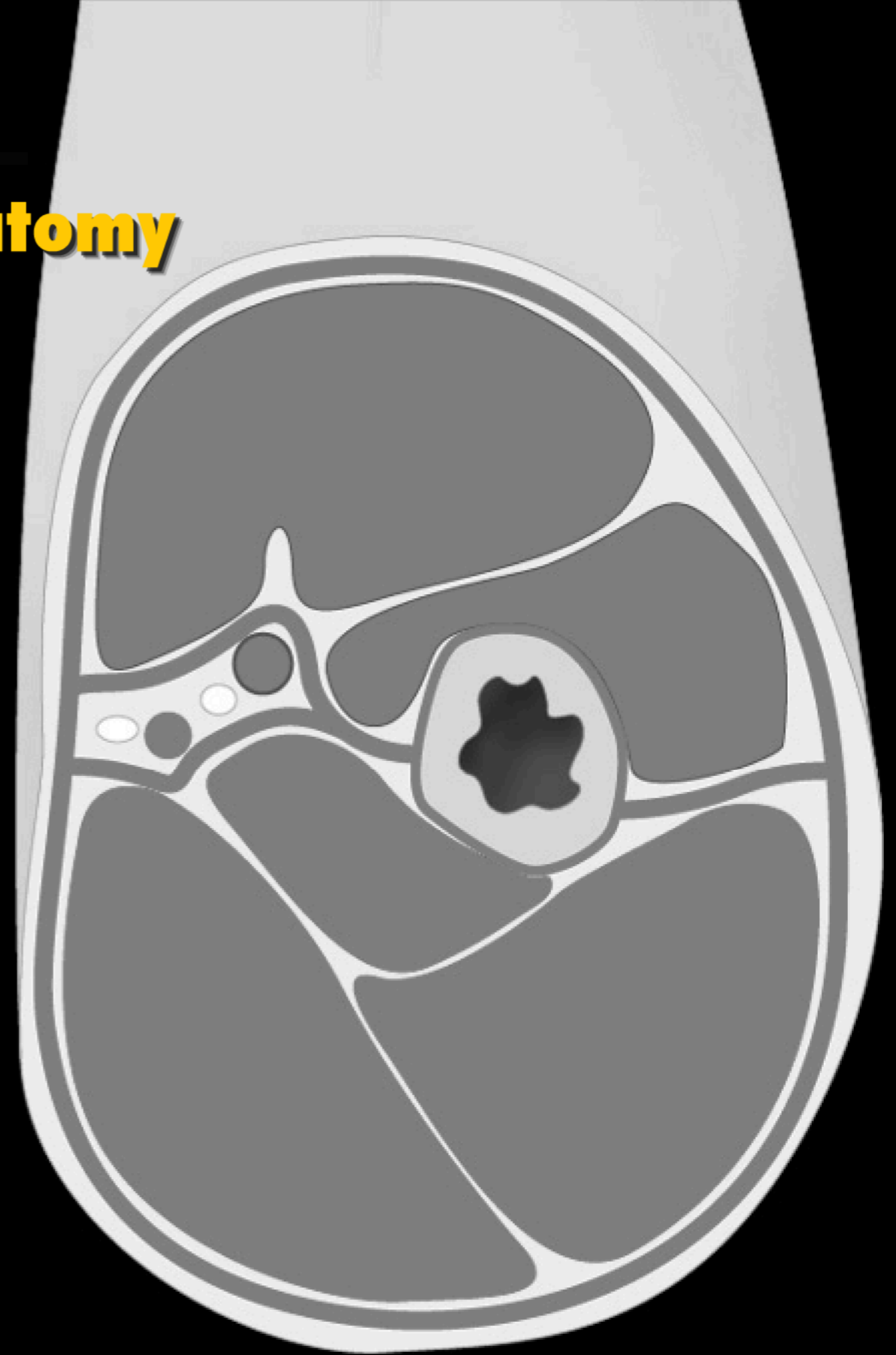


I know my
anterior and
posterior divisions

Limb Design

Compartmentalization of the Limb

Muscular Compartment Anatomy

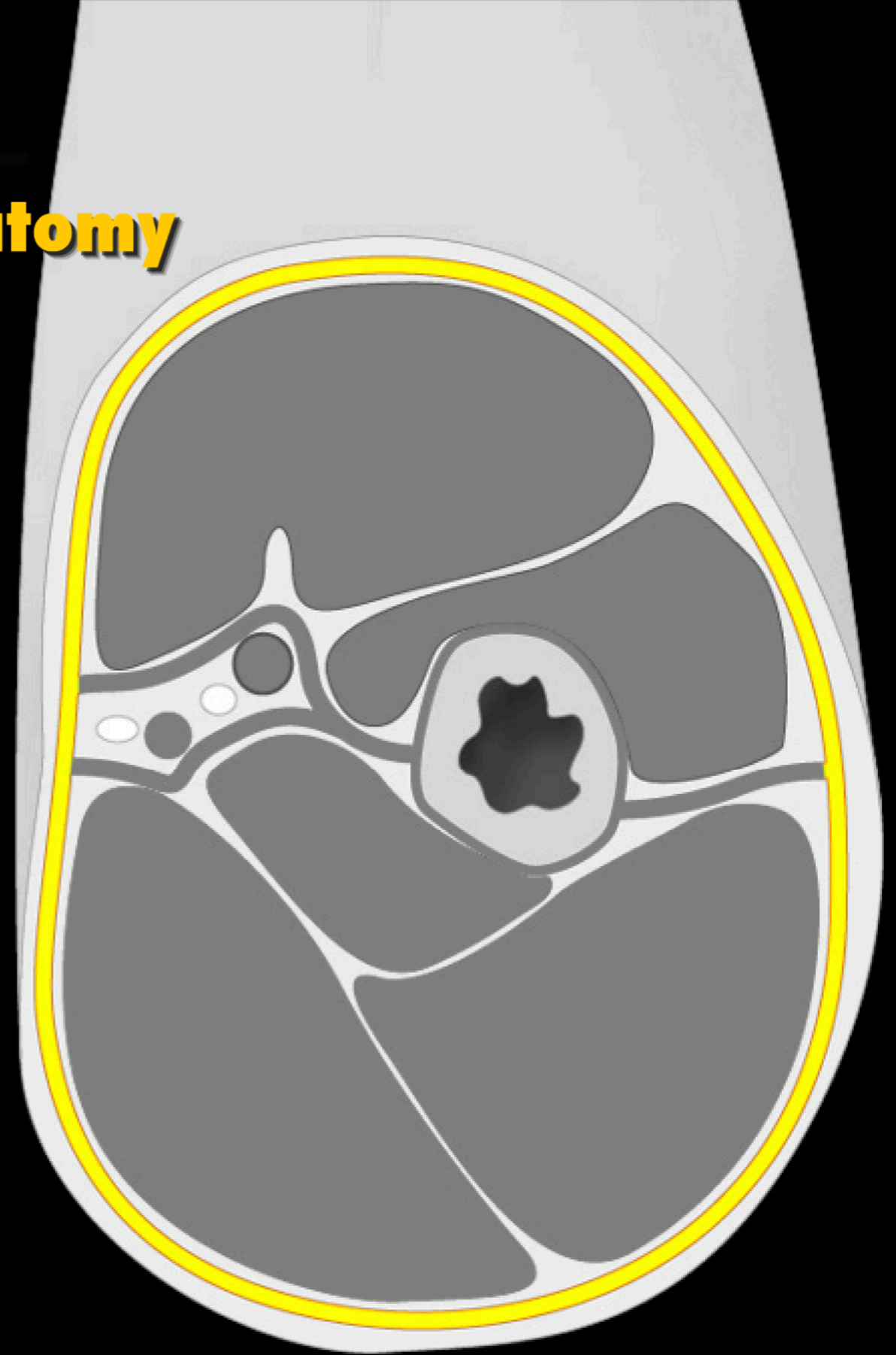


Limb Design

Compartmentalization of the Limb

Muscular Compartment Anatomy

Fascia

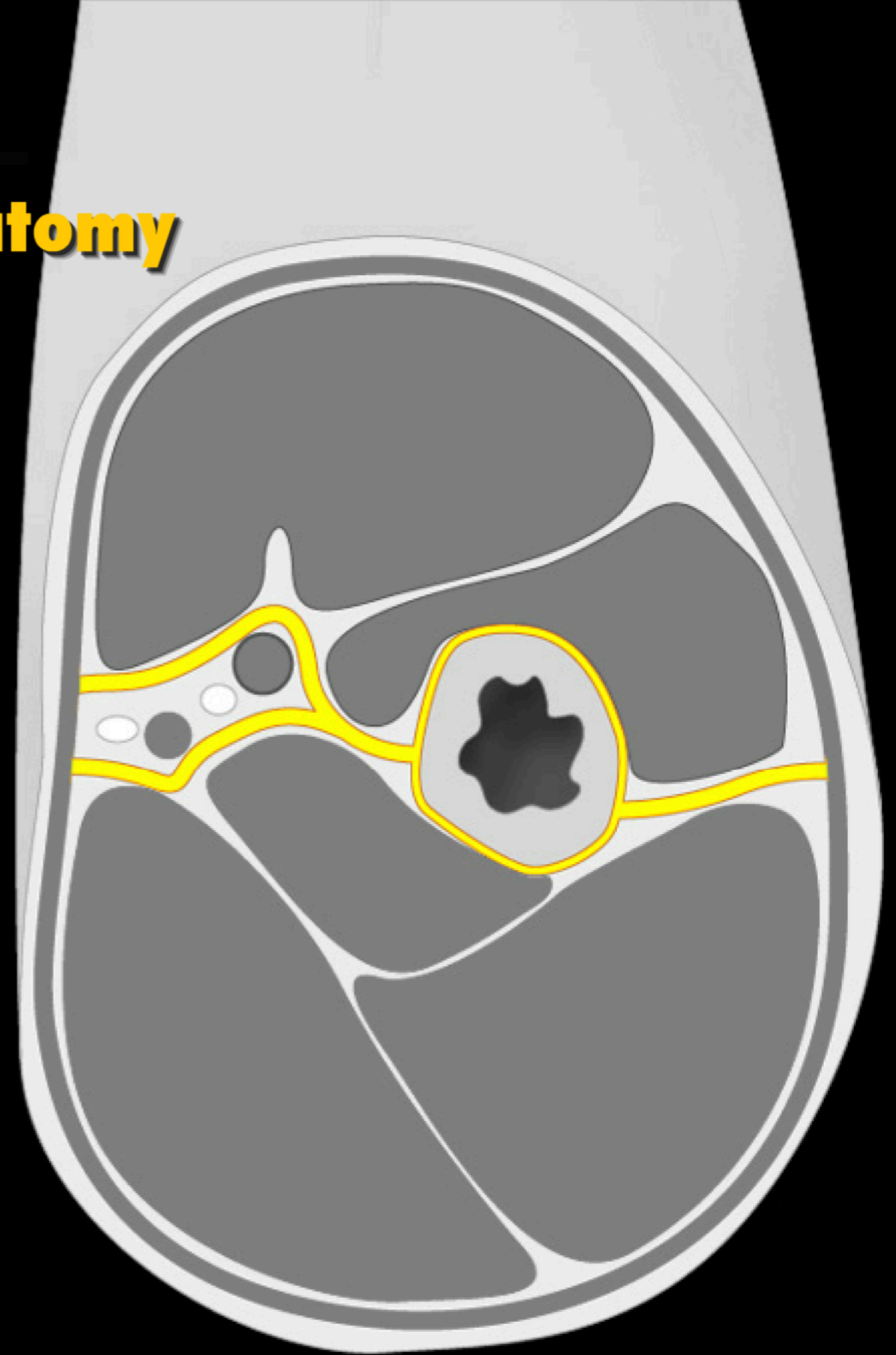


Limb Design

Compartmentalization of the Limb

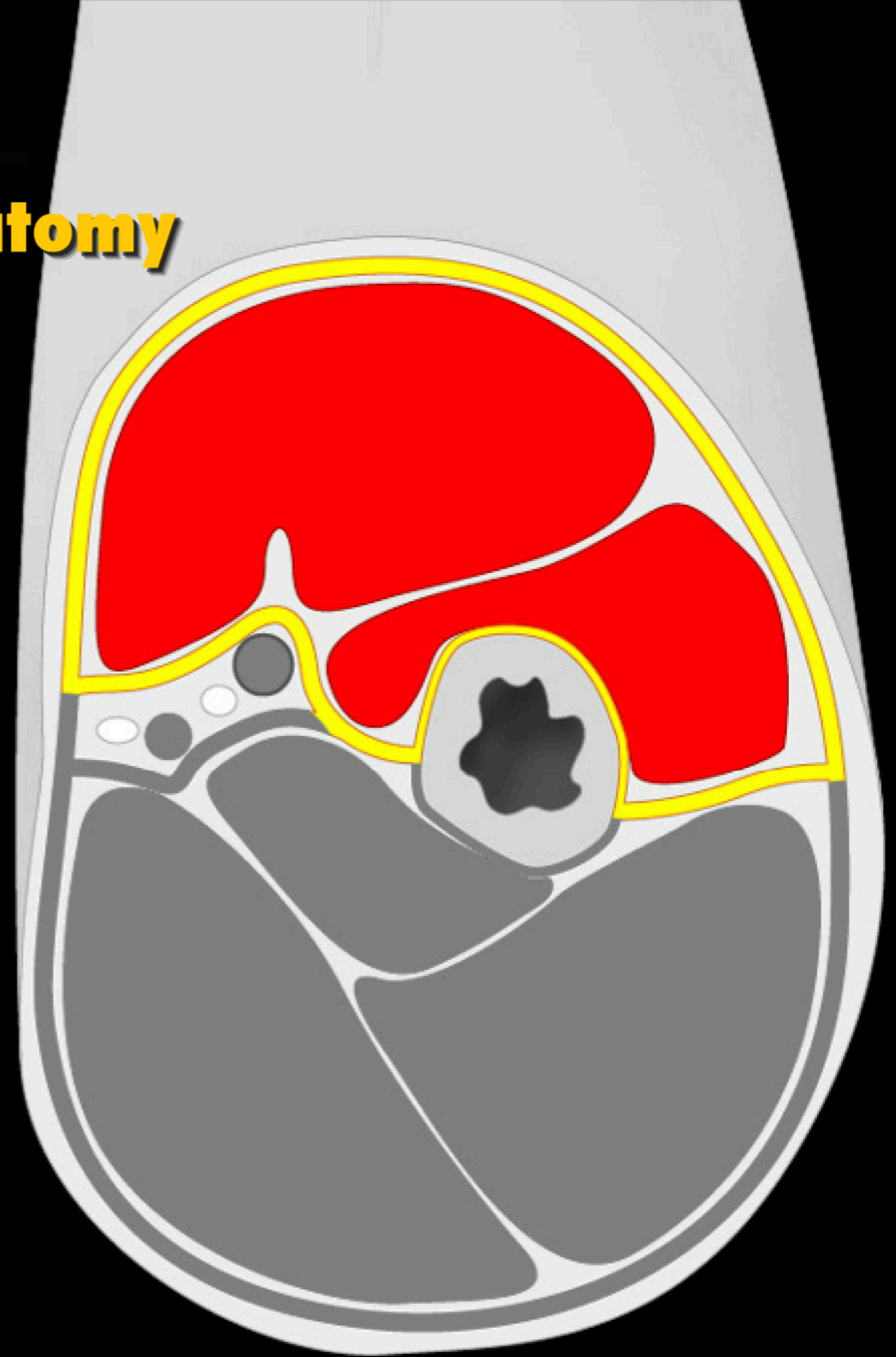
Muscular Compartment Anatomy

Intermuscular septum



Muscular Compartment Anatomy

Muscle compartment - anterior

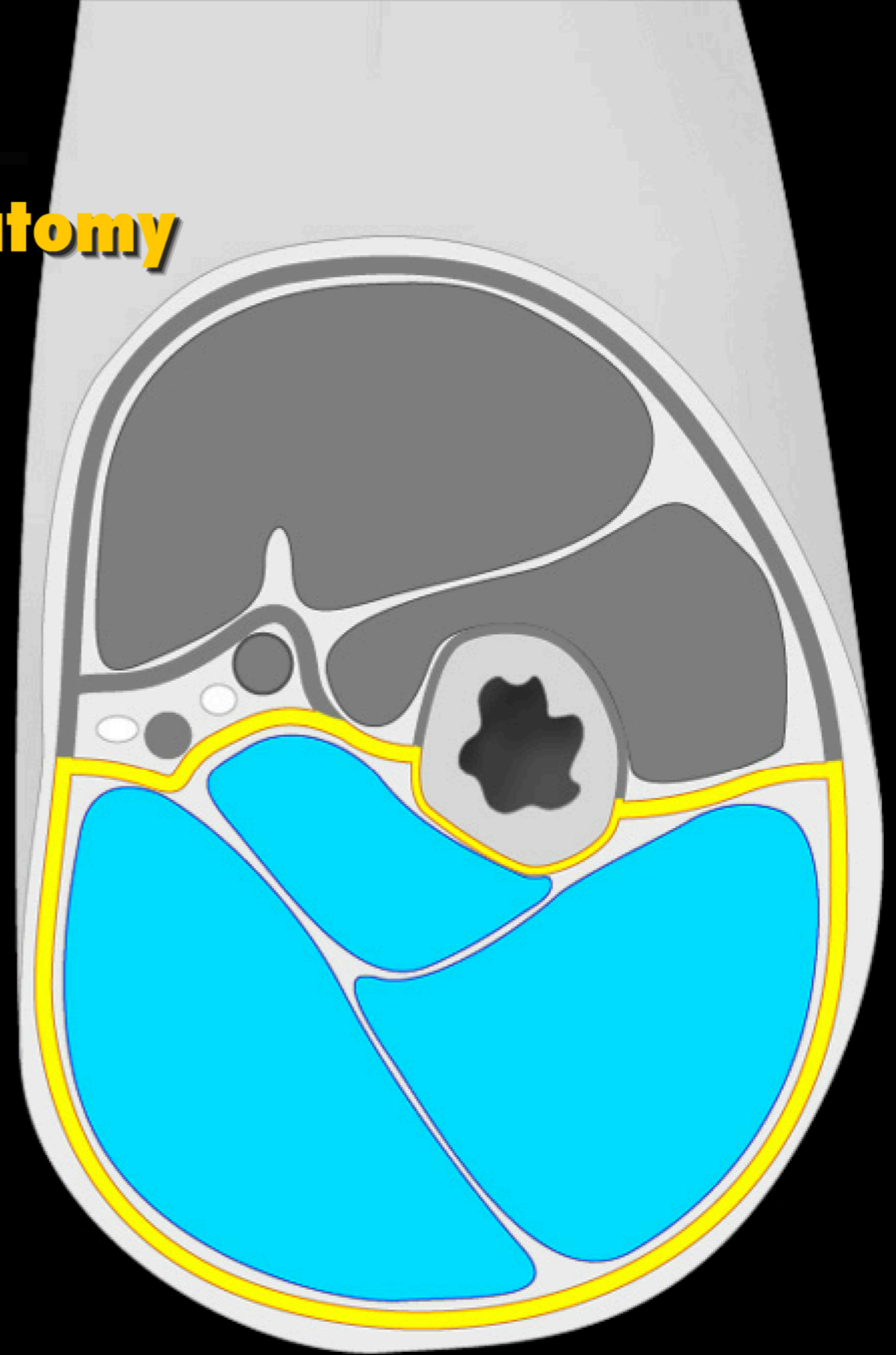


Limb Design

Compartmentalization of the Limb

Muscular Compartment Anatomy

Muscle compartment - posterior

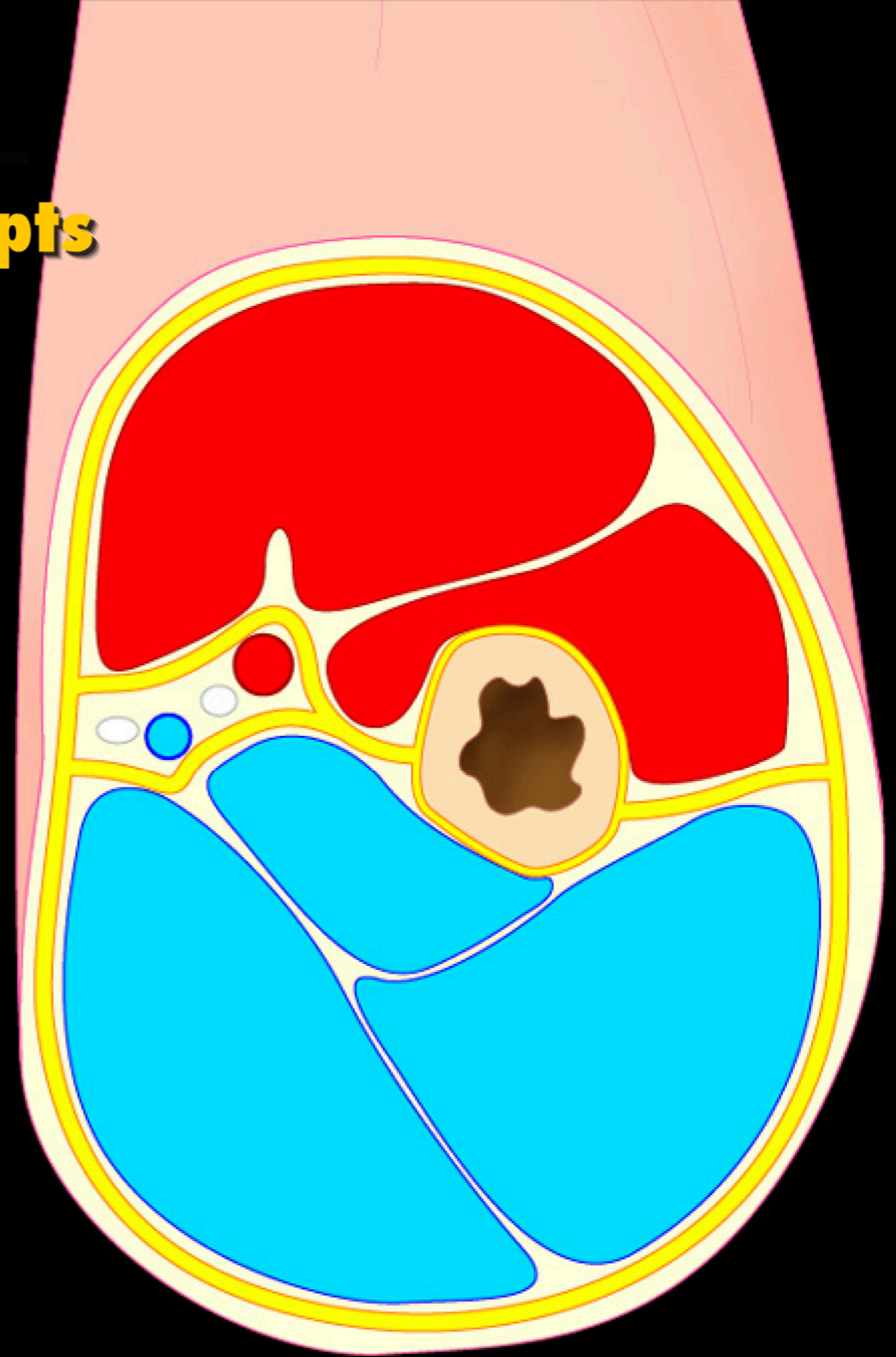


Limb Design

Compartmentalization of the Limb

Muscle Compartment Concepts

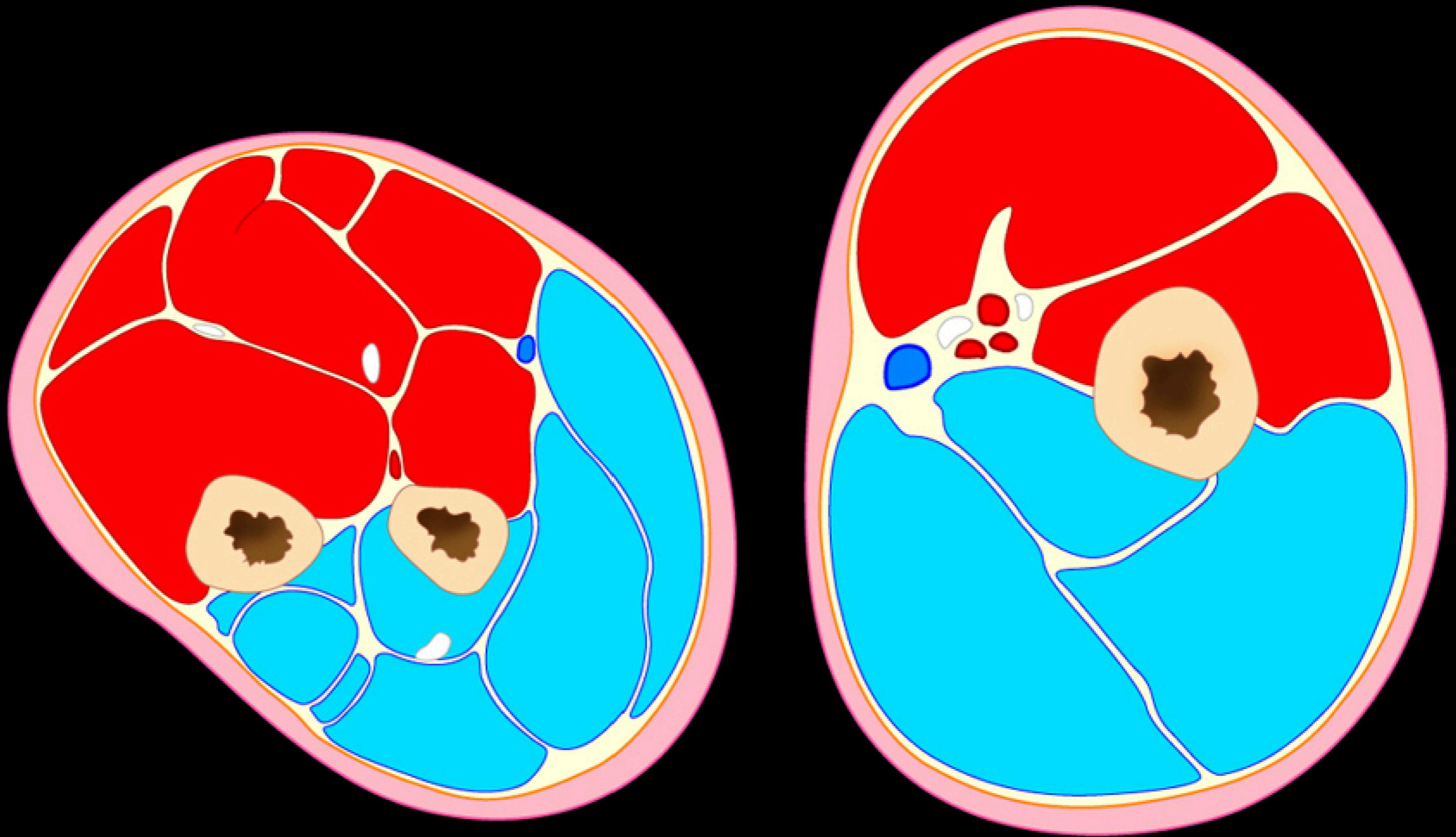
- Common attachments
- Common actions
- Common innervation
- Common blood supply



Limb Design

Compartments of the Superior Limb

Preview



Limb Design

Learning Muscles

